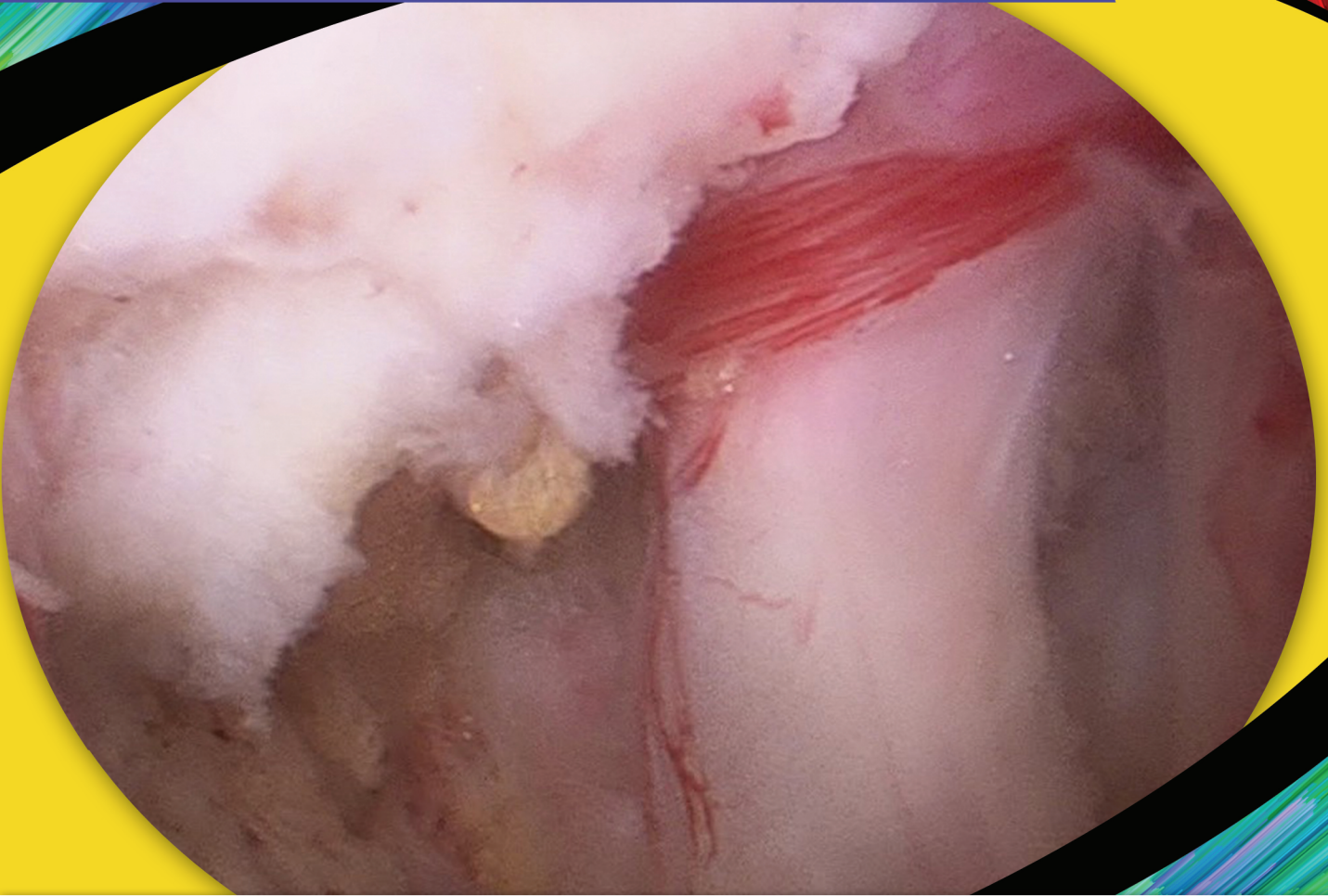


CONTEMPORARY ENDOSCOPIC SPINE SURGERY CERVICAL SPINE

VOLUME 1



Editors:
Kai-Uwe Lewandrowski
Jorge Felipe Ramírez León
Anthony Yeung

Bentham Books

Contemporary Endoscopic Spine Surgery

(Volume 1)

Cervical Spine

Edited by

Kai-Uwe Lewandrowski

Center For Advanced Spine Care

Tucson

Arizona

USA

Jorge Felipe Ramírez León

Fundación Universitaria Sanitas

Clínica Reina Sofía – Clínica Colsanitas

Centro de Columna – Cirugía Mínima Invasiva

Bogotá, D.C.

Colombia

Anthony Yeung

University of New Mexico

School of Medicine

Albuquerque

New Mexico

Assistant Editors

Hyeun-Sung Kim

*Department of Neurosurgery
Nanoori Gangnam Hospital
Seoul
Republic of Korea*

Xifeng Zhang

*Department of Orthopedics
First Medical Center
PLA General Hospital
Beijing 100853
China*

Gun Choi

*Neurosurgeon and Minimally Invasive Spine Surgeon
President Pohang Wooridul Hospital
South Korea*

Stefan Hellinger

*Department of Orthopedic Surgery
Arabellaklinik
Munich
Germany*

Álvaro Dowling

*Endoscopic Spine Clinic
Santiago
Chile*

Contemporary Endoscopic Spine Surgery

(Volume 1)

Cervical Spine

Editors: Kai-Uwe Lewandrowski, Jorge Felipe Ramírez León and Anthony Yeung

Assistant Editors: Hyeun-Sung Kim, Xifeng Zhang, Gun Choi, Stefan Hellinger and Álvaro Dowling

ISSN (Online): 4: 32/; 74Z

ISSN (Print): 4: 32/; 75:

ISBN (Online): 978-981-4998-63-5

ISBN (Print): 978-981-4998-64-2

ISBN (Paperback): 978-981-4998-65-9

©2021, Bentham Books imprint.

Published by Bentham Science Publishers Pte. Ltd. Singapore. All Rights Reserved.

BENTHAM SCIENCE PUBLISHERS LTD.

End User License Agreement (for non-institutional, personal use)

This is an agreement between you and Bentham Science Publishers Ltd. Please read this License Agreement carefully before using the ebook/echapter/ejournal (“**Work**”). Your use of the Work constitutes your agreement to the terms and conditions set forth in this License Agreement. If you do not agree to these terms and conditions then you should not use the Work.

Bentham Science Publishers agrees to grant you a non-exclusive, non-transferable limited license to use the Work subject to and in accordance with the following terms and conditions. This License Agreement is for non-library, personal use only. For a library / institutional / multi user license in respect of the Work, please contact: permission@benthamscience.net.

Usage Rules:

1. All rights reserved: The Work is the subject of copyright and Bentham Science Publishers either owns the Work (and the copyright in it) or is licensed to distribute the Work. You shall not copy, reproduce, modify, remove, delete, augment, add to, publish, transmit, sell, resell, create derivative works from, or in any way exploit the Work or make the Work available for others to do any of the same, in any form or by any means, in whole or in part, in each case without the prior written permission of Bentham Science Publishers, unless stated otherwise in this License Agreement.
2. You may download a copy of the Work on one occasion to one personal computer (including tablet, laptop, desktop, or other such devices). You may make one back-up copy of the Work to avoid losing it.
3. The unauthorised use or distribution of copyrighted or other proprietary content is illegal and could subject you to liability for substantial money damages. You will be liable for any damage resulting from your misuse of the Work or any violation of this License Agreement, including any infringement by you of copyrights or proprietary rights.

Disclaimer:

Bentham Science Publishers does not guarantee that the information in the Work is error-free, or warrant that it will meet your requirements or that access to the Work will be uninterrupted or error-free. The Work is provided "as is" without warranty of any kind, either express or implied or statutory, including, without limitation, implied warranties of merchantability and fitness for a particular purpose. The entire risk as to the results and performance of the Work is assumed by you. No responsibility is assumed by Bentham Science Publishers, its staff, editors and/or authors for any injury and/or damage to persons or property as a matter of products liability, negligence or otherwise, or from any use or operation of any methods, products instruction, advertisements or ideas contained in the Work.

Limitation of Liability:

In no event will Bentham Science Publishers, its staff, editors and/or authors, be liable for any damages, including, without limitation, special, incidental and/or consequential damages and/or damages for lost data and/or profits arising out of (whether directly or indirectly) the use or inability to use the Work. The entire liability of Bentham Science Publishers shall be limited to the amount actually paid by you for the Work.

General:

1. Any dispute or claim arising out of or in connection with this License Agreement or the Work (including non-contractual disputes or claims) will be governed by and construed in accordance with the laws of Singapore. Each party agrees that the courts of the state of Singapore shall have exclusive jurisdiction to settle any dispute or claim arising out of or in connection with this License Agreement or the Work (including non-contractual disputes or claims).
2. Your rights under this License Agreement will automatically terminate without notice and without the

need for a court order if at any point you breach any terms of this License Agreement. In no event will any delay or failure by Bentham Science Publishers in enforcing your compliance with this License Agreement constitute a waiver of any of its rights.

3. You acknowledge that you have read this License Agreement, and agree to be bound by its terms and conditions. To the extent that any other terms and conditions presented on any website of Bentham Science Publishers conflict with, or are inconsistent with, the terms and conditions set out in this License Agreement, you acknowledge that the terms and conditions set out in this License Agreement shall prevail.

Bentham Science Publishers Pte. Ltd.

80 Robinson Road #02-00

Singapore 068898

Singapore

Email: subscriptions@benthamscience.net



ENDORSEMENTS

ISASS



The International Society for the Advancement of Spine Surgery (ISASS; formerly The Spine Arthroplasty Society) has its roots in motion preservation as an alternative to fusion. Since then, it has worked to achieve its mission of acting as a global, scientific and educational society with a surgeon-centered focus. ISASS was organized to provide an independent venue to discuss and address the issues involved with all aspects of basic and clinical science of motion preservation, stabilization, innovative technologies, MIS procedures, biologics, and other fundamental topics to restore and improve motion and function of the spine. ISASS has a robust international membership of orthopedic and neurosurgery spine surgeons and scientists. ISASS is dedicated to advancing evolutionary and innovative spinal techniques and procedures such as endoscopic spine surgery. Every editor of *Contemporary Endoscopic Spine Surgery* represents ISASS as a member, author, reviewer, or editor of its quarterly circulation – The International Journal of Spine Surgery (IJSS). The contributors of *Contemporary Endoscopic Spinal Surgery* have succeeded in compiling an exhaustive and up-to-date reference text. It is an example of our society's mission pursuit of surgeon education and scientific study. It is my pleasure to endorse this comprehensive text on behalf of ISASS.

Domagoj Coric

President

International Society for the Advancement of Spine Surgery (ISASS)

Illinois

USA

SBC

Founded on October 12, 1994, the Brazilian Spine Society (Sociedade Brasileira de Coluna - SBC) is a scientific, non-profit organization whose primary objective is the advancement of spine surgery through basic research and clinical study in orthopedics and neurosurgery. SBC is actively engaged in the accreditation and continued education of spine surgeons in Brazil. It prides itself on bringing the latest high-grade scientific evidence on novel technological advances and therapies to its professional members. SBC pursues this mission with its quarterly circulation Coluna/ Columna and its online courses, including Introduction to Endoscopy. The authors and editors of Contemporary Endoscopic Spine Surgery have put forward a comprehensive reference text essential to SBC's core curriculum of teaching spinal endoscopy to the next generation of surgeons. The presented clinical protocols for the endoscopic treatment of cervical and lumbar spine conditions are vetted and validated by peer-reviewed articles published by its contributors. It is my pleasure to endorse Contemporary Endoscopic Spine Surgery on behalf of the Brazilian Spine Society.

Cristiano Magalhães Menezes

President of the Brazilian Spine Society (Sociedade Brasileira de Coluna - SBC)
São Paulo
Brazil

MISS OF COA



The Minimally Invasive Spine Surgery (MISS) of Chinese Orthopaedic Association (COA) was founded in 2003, which is one of the most special subsidiary societies of Chinese Medical Association, aiming to promote and develop minimally invasive orthopedics especially spine surgeries in China.

The MISS society organizes global discussions and encourages our members to participate international efforts and cooperation to improve surgeon education. With this mission in mind, it is my pleasure to endorse Contemporary Endoscopic Spine Surgery on behalf of the MISS of COA. Many international editors and contributors are from China, who have made great efforts, contributions and dedications to this book. They share with and update readers all over the world about the latest endoscopic spinal surgery techniques. I am confident that *Contemporary Endoscopic Spinal Surgery* can be a textbook for spine surgeons. It should be used as medical school advanced lessons materials for continuing education courses. In sum, it is my pleasure and honor to support it on behalf of the MISS of COA.

Huilin Yang

Chairman of MISS of COA

Professor & Chairman of Orthopedic Department
The First Affiliated Hospital of Soochow University
Suzhou
China

SICCM I



SICCM I (Sociedad Interamericana De Cirugia De Columna Minimamente Invasive) was founded in 2006 with similar objectives pursued by the editors of Contemporary Endoscopic Spine Surgery: the advancement and mainstreaming of minimally invasive spine surgery (MIS). SICCM I members joined to implement MIS in all countries of South America, the Caribbean, Central America, and North America. Endoscopic surgery is performed by many of its key opinion leaders at the highest level, some of which have contributed to this multi-volume text. Four of the editors are active SICCM I members in leadership positions. The book contents are exhaustive and comprehensive, encompassing topics of the cervical and lumbar spine and advanced technology applications. Contemporary Endoscopic Spine Surgery will serve as SICCM I's core curriculum and course material for endoscopic surgery of the spine. It is my pleasure to endorse it on behalf of SICCM I.

President of SICCM I
Manuel Rodriguez
President-Elect of SICCM I, Department of Neurosurgery
ABC Medical Center
Ciudad de México, Mexico

SBMT



As a nonprofit organization, the Society for Brain Mapping and Therapeutics (SBMT) focuses on improving patient care by translating new technologies into life-saving diagnostic and therapeutic procedures. Contemporary Endoscopic Spine Surgery is a prime example of achieving excellence in education and scientific discovery. Authors and editors from around the globe came together to present the reader with the most up-to-date endoscopic spine surgery protocols and their supporting clinical evidence. SBMT has an active spine section led by productive innovator surgeons – some of which have demonstrated their leadership with their editorial contributions to *Contemporary Endoscopic Spinal Surgery*. The editors have embraced multidisciplinary collaborations across many cultural and geographic barriers. Their effort represents one of the core principles of SBMT's mission: to identify and bridge gaps in modern patient care with technological advances. It is my pleasure to endorse *Contemporary Endoscopic Spinal Surgery* on behalf of SBMT.

Babak Kateb

Founding Chairman of the Board of Directors
CEO and Scientific Director of SBMT
Californias
USA

SILACO



SILICO (Sociedad Ibero Latinoamericana de Columna) had its beginnings in the meetings of the Scoliosis Research Society with the first Hispano-American Congress held in 1991 in Buenos Aires Argentina. Since then, it has morphed into an organization that promotes the study of treatments and prevention of spinal conditions by bringing together spine care professionals from all subspecialties. The scientific activities of our biannual Ibero-Latin American Congress are focused on the promotion of surgeon education to the highest academic standards via international relationships between members from the Americas, Spain and Portugal.

Contemporary Endoscopic Spine Surgery resembles such a collaborative effort where authors worldwide have come together to update the reader on the latest endoscopic spinal surgery techniques.

SILACO has incorporated Contemporary Endoscopic Spine Surgery into its core curriculum and plans on using it as course material for its continuing education courses. It is my pleasure to endorse it on behalf of SILACO.

Jaime Moyano

President of SILACO

Editor Revista De Sociedad Ecuatoriana De Ortopedia y Traumatología
de la Sociedad Ecuatoriana De Ortopedia Y Traumatología
Quito, Ecuador

SOMEEC



SOMEEC- Sociedad Mexicana de Endoscopia de Columna- is Mexico's prime organization uniting spine surgeons with a diverse training background having a fundamental interest in endoscopic surgery. SOMEEC organizes annual meetings where member surgeons and international faculty update each other on their latest clinical research to promote spine care *via* endoscopic spinal surgery technique. Two of the senior lead editors of *Contemporary Endoscopic Spinal Surgery* have been active international supporters of SOMEEC. I am pleased to endorse their latest three-volume reference text, which will become an integral centerpiece of SOMEEC's continuing medical educational programs.

Cecilio Quinones

Past President of the Sociedad Mexicana de Endoscopia de Columnas

KOESS



The Korean Research Society of Endoscopic Spine Surgery (KOESS) was established in 2017. KOESS was founded to bring endoscopic spine surgeons in the Republic of Korea together to advance the subspecialty of endoscopic spine surgery with high-quality clinical research. It is reflected in *Contemporary Endoscopic Spine Surgery* by the numerous contributions of Korean authors. It is *Contemporary Endoscopic Spine Surgery*. It is my pleasure to endorse it on behalf of KOESS.

Hyeun-Sung Kim (Harrison Kim)

President of the Korean Research Society of the Endoscopic Spine Society
(KOESS)
Seoul

Republic of Korea

KOMISS



Since its establishment in 2002, the *Korean Minimally Invasive Spinal Surgery Society* (KOMISS) has had a leading role in developing new clinically applicable technologies to advance patient care with less invasive yet more effective therapies. The superiority of minimally invasive spine surgery in Korea is demonstrated by its competitiveness on the world stage at the highest academic level. It is reflected in *Contemporary Endoscopic Spine Surgery* by the numerous Korean authors who have contributed to this timely reference text with their groundbreaking clinical research on endoscopic spine surgery. I am proud of their accomplishments and want to congratulate them on acting as KOMISS ambassadors by carrying the message of Korean excellence in minimally invasive spinal surgery the world over within *Contemporary Endoscopic Spine Surgery*. It is my pleasure to endorse it on behalf of KOMISS.

Dae Hyun Kim
President of KOMISS
Seoul
Republic of Korea

NATIONAL ACADEMY OF MEDICINE OF COLOMBIA



After reviewing the table of content and some representative chapters, I am happy to inform you that the Board of Directors of the National Academy of Medicine of Colombia grants academic endorsement of your book series entitled Contemporary Endoscopy Spine Surgery. Kai-Uwe Lewandrowski, Jorge Felipe Ramírez, and Anthony Yeung produced a text of great interest and scientific impact.

On behalf of the National Academy of Medicine, I would like to express my admiration and respect for your dedication to scientific research that led to this great work's culmination. It meets the high standards required by our National Academy to support such a production spearheaded by one of our most esteemed members - Dr. Jorge Felipe Ramírez.

Gustavo Landazabal Bernal
General Secretary
National Academy of Medicine of Colombia
Bogota, Colombia

IITS



International Intradiscal Therapy Society

The International Intradiscal Therapy Society (IITS) was founded in 1987, initially headquartered in Belgium, Wisconsin, and led by Dr. Eugene Nordby, the first Executive Director of IITS. Members were primarily orthopaedic surgeons, anesthesiologists, radiologists, and rheumatologists dedicated to the treatment, research, and education involving The FDA-approved and validated level I studies that supported intradiscal spinal therapies.

From 2013-2017, the society began operating under International Intradiscal and Transforaminal Therapy Society (IITTSS) to reflect the advancements in endoscopic spine surgery augmenting Intradiscal therapy. The organization wanted to include and reflect the state-of-the-art evolution in intradiscal therapy with advances by intradiscal visualization of pain generators through the endoscope. However, the society reverted to IITS.

IITS now sponsors workshops on intradiscal therapy in conjunction with other International societies when it lost its original pharma support. IITS disseminates a newsletter to provide its membership, other healthcare professionals, and the general public information on the safest and cost-effective techniques to treat conditions such as herniated nucleus pulposus and other intradiscal spinal disorders.

IITS is a 501C3 non-profit organization whose focus is on intradiscal therapy aided by the endoscope as the least invasive, visually-guided treatment for discogenic pain, including extra-discal and complex foraminal decompression and stabilization procedures. The disc has been validated as the primary initial source of common back pain.

Two of the senior lead editors of Contemporary Endoscopic Spinal Surgery have been in active leadership roles in International Spine Organizations as consultants, full and associate professors, and directors. I am pleased to endorse their latest three-volume reference text, which will become integral to IITS' ongoing course programs.

Anthony Yeung
Executive Director of IITS
Desert Institute for Spine Care
Phoenix, Arizona
USA

SLAOT



The Sociedad Latinoamericana de Ortopedia y Traumatología (SLAOT)/ Latin American Society of Orthopaedics and Traumatology is a non-profit, autonomous, scientific organization of orthopaedic surgeons and orthopaedic care professionals. SLAOT has an organization structure that brings together professionals with a diverse scientific interest. It promotes continuous professional development and education at the highest level. *Contemporary Endoscopic Spine Surgery* is of interest to SLAOT because of its illustrative use of cutting-edge technology and discussion of validated clinical endoscopic spinal surgery protocols. It is my pleasure to endorse *Contemporary Endoscopic Spine Surgery* on behalf of SLAOT.

Horacio Caviglia
President of SLAOT FEDERACION
USA

CONTENTS

PREFACE	i
LIST OF CONTRIBUTORS	ii
CHAPTER 1 CERVICAL ENDOSCOPY: HISTORICAL PERSPECTIVES, PRESENT & FUTURE	1
<i>Kai-Uwe Lewandrowski, Jin-Sung Kim, Stefan Hellinger and Anthony Yeung</i>	
INTRODUCTION	2
RECYCLED TRENDS	2
THE CERVICAL ENDOSCOPE OF THE FUTURE	3
THE OBJECTIVE	4
THE ADOPTION & TRAINING DILEMMA	4
THE PARADIGM SHIFT	4
THE BENEFITS	5
THE ACCEPTANCE LAG	5
THE HISTORY	6
LASERS	7
RADIOFREQUENCY	9
NEW LANDMARK CLINICAL OUTCOME STUDIES	11
CONCLUSION	15
CONSENT FOR PUBLICATION	15
CONFLICT OF INTEREST	15
ACKNOWLEDGEMENTS	15
REFERENCES	15
CHAPTER 2 ANESTHESIA FOR MINIMALLY INVASIVE SURGERY OF THE CERVICAL SPINE	31
<i>João Abrão, Kai-Uwe Lewandrowski and Álvaro Dowling</i>	
INTRODUCTION	32
ANESTHESIA STRATEGIES	32
SEDATION	33
ANESTHESIA FOR CERVICAL ENDOSCOPY IN AMBULATORY SURGERY CENTER (ASC)	34
SEDATIVES	35
Benzodiazepines	35
Propofol	35
Dexmedetomidine	36
Remifentanyl	37
Ketamine	37
DISCUSSION	37
CONCLUSIONS	39
CONSENT FOR PUBLICATION	39
CONFLICT OF INTEREST	39
ACKNOWLEDGEMENTS	39
REFERENCES	39
CHAPTER 3 ALGORITHMS TO CHOOSE BETWEEN ANTERIOR AND POSTERIOR CERVICAL ENDOSCOPY	43
<i>Álvaro Dowling, Kai-Uwe Lewandrowski and Helton Delfino</i>	
INTRODUCTION	44
HERNIATED DISC	45

ALGORITHM FOR HERNIATED DISC	46
ALGORITHM FOR FORAMINAL STENOSIS	47
ALGORITHM FOR CENTRAL CERVICAL STENOSIS	49
THE IMPACT OF TECHNOLOGY ADVANCES	51
DISCUSSION	52
CONCLUSIONS	54
CONSENT FOR PUBLICATION	55
CONFLICT OF INTEREST	55
ACKNOWLEDGEMENTS	55
REFERENCES	55
CHAPTER 4 CONTEMPORARY CLINICAL DECISION MAKING IN FULL ENDOSCOPIC CERVICAL SPINE SURGERY	62
<i>Álvaro Dowling, Kai-Uwe Lewandrowski, and Helton Delfino</i>	
INTRODUCTION	63
CLINICAL AND RADIOGRAPHIC EVALUATION	64
MAGNETIC RESONANCE IMAGING	66
ANATOMIC CONSIDERATION	66
Anterior Approach	66
Prevertebral Structures	67
Carotid Artery Bifurcation	67
Posterior Approach	68
Length of the Exposed Nerve Root	68
Bone Resection	69
Relation Between Nerve Root & Disc	69
CLASSIFICATION SYSTEMS FOR SURGICAL DECISION MAKING	71
Classification of Cervical Foraminal Stenosis	71
Classification of Cervical Canal Stenosis	71
Classification of Cervical Disc Herniations	73
Cervical Myelopathy Classification	73
CLINICAL DECISION MAKING	74
For Herniated Disc	74
For Stenosis	74
THE SURGEON FACTOR & HOW TO ARRIVE AT THE PREFERRED PROCEDURE	75
DISCUSSION	76
CONCLUSIONS	76
CONSENT FOR PUBLICATION	77
CONFLICT OF INTEREST	77
ACKNOWLEDGEMENTS	77
REFERENCES	77
CHAPTER 5 INDICATIONS AND OUTCOMES WITH ENDOSCOPIC POSTERIOR CERVICAL RHIZOTOMY	82
<i>Kai-Uwe Lewandrowski, Ralf Rothoerl, Stefan Hellinger and Hyeun Sung Kim</i>	
INTRODUCTION	83
SURGICAL TECHNIQUE	85
CLINICAL SERIES	87
DISCUSSION	89
CONCLUSION	90
CONSENT FOR PUBLICATION	91
CONFLICT OF INTEREST	91

ACKNOWLEDGEMENTS	91
REFERENCES	91
CHAPTER 6 ANTERIOR ENDOSCOPIC CERVICAL DISCECTOMY	94
<i>Malcolm Pestonji, Álvaro Dowling, Helton Delfino and Kai-Uwe Lewandrowski</i>	
INTRODUCTION	95
ANATOMICAL CONSIDERATIONS	95
ENDOSCOPIC INSTRUMENTATION	97
POSITIONING & SETUP	98
PEARLS OF SETUP & ACCESS	98
TWO FINGER MOBILIZATION & NEEDLE PLACEMENT	99
ENDOSCOPIC SURGERY PEARLS	101
POSTOPERATIVE MANAGEMENT	102
CLINICAL SERIES	103
DISCUSSION	103
CONCLUSIONS	105
CONSENT FOR PUBLICATION	105
CONFLICT OF INTEREST	106
ACKNOWLEDGEMENTS	106
REFERENCES	106
CHAPTER 7 ANTERIOR TRANSCORPOREAL APPROACH OF PERCUTANEOUS ENDOSCOPIC CERVICAL DISCECTOMY	108
<i>Zhong-Liang Deng, Lei Chu, Liang Chen and Jun-Song Yang</i>	
INTRODUCTION	109
SURGICAL TECHNIQUE	110
CLINICAL SERIES	114
DISCUSSION	117
CONCLUSIONS	120
CONSENT FOR PUBLICATION	120
CONFLICT OF INTEREST	121
ACKNOWLEDGEMENTS	121
REFERENCES	121
CHAPTER 8 ANTERIOR ENDOSCOPIC CERVICAL DISCECTOMY AND FORAMINOPLASTY FOR HERNIATED DISC AND LATERAL CANAL STENOSIS	126
<i>Jorge Felipe Ramírez León, José Gabriel Rugeles Ortiz, Carolina Ramírez Martínez, Nicolás Prada Ramírez, Enrique Osorio Fonseca and Gabriel Oswaldo Alonso Cuéllar</i>	
INTRODUCTION	127
BACKGROUND	127
OBJECTIVE	128
ANTERIOR ENDOSCOPIC CERVICAL FORAMINOPLASTY	128
Indications	128
Contraindications	129
Patient Positioning & Anesthesia	129
Equipment & Instrumentation	129
SURGICAL TECHNIQUE	130
LEARNING CURVE	133
CLINICAL OUTCOMES	134
DISCUSSION	134
CONCLUSIONS	135
CONSENT FOR PUBLICATION	135

CONFLICT OF INTEREST	135
ACKNOWLEDGEMENTS	136
REFERENCES	136
CHAPTER 9 POSTERIOR FULL ENDOSCOPIC CERVICAL DISCECTOMY & FORAMINOTOMY	139
<i>Alvaro Dowling, Kai-Uwe Lewandrowski and Hyeun Sung Kim</i>	
INTRODUCTION	140
CLINICAL PRESENTATION	140
ADVANTAGES OF ENDOSCOPICALLY VISUALIZED POSTERIOR FORAMINOTOMY	141
INDICATIONS & CONTRAINDICATIONS	142
POSITIONING & ANESTHESIA	142
OR SETUP	143
SURGICAL TECHNIQUE	145
The Trans-“V-point” Foraminotomy Technique	146
Posterior Cervical Disectomy with Neural Retraction	147
CLINICAL SERIES	148
DISCUSSION	149
CONCLUSIONS	152
CONSENT FOR PUBLICATION	152
CONFLICT OF INTEREST	152
ACKNOWLEDGEMENTS	152
REFERENCES	153
CHAPTER 10 POSTERIOR ENDOSCOPIC DECOMPRESSION FOR CERVICAL SPONDYLOTIC MYELOPATHY	156
<i>Yuan Heng, Zhang Xi-feng, Zhang Lei-ming, Yan Yu-qiu, Liu Yan-kang and Kai-Uwe Lewandrowski</i>	
INTRODUCTION	157
CLINICAL SERIES	158
ENDOSCOPIC SURGICAL TECHNIQUE	158
POSTOPERATIVE REHABILITATION	159
EXEMPLARY CASES	160
CLINICAL OUTCOMES	163
DISCUSSION	165
CONCLUSIONS	167
CONSENT FOR PUBLICATION	167
CONFLICT OF INTEREST	167
ACKNOWLEDGEMENTS	167
REFERENCES	167
CHAPTER 11 FULL ENDOSCOPIC PARTIAL PEDICULOTOMY, PARTIAL VERTEBROTOMY TECHNIQUE FOR CERVICAL DEGENERATIVE SPINAL DISEASE	172
<i>Pang Hung Wu, Hyeun Sung Kim and Il-Tae Jang</i>	
INTRODUCTION	173
RATIONALE	174
Anatomical Relationship of Cervical Disc, Pedicle & Exiting Nerve Root	174
Current Limitation of Posterior Endoscopic Cervical Foraminotomy and Discectomy	174
Concept of Subneural Space Creation for Endoscopic Instruments	175
Concepts of Creation of Sub-Corporeal Space	175
Preoperative Evaluation	175

Anesthesia and Positioning	176
SURGICAL STEPS	176
Identification of Level and Safe Docking of the Endoscope	176
Superficial Soft Tissue Dissection & Bone Drilling	177
Deep Bony Dissection	178
Partial Pediculotomy	178
Exposure of Neural Elements	178
Decompression of Uncovertebral Joint in Cases of Foraminal Stenosis	179
Partial Vertebrotoomy (Optional)	179
Discectomy	179
Hemostasis & Closure	179
POTENTIAL RISKS	179
POSTOPERATIVE AND REHABILITATION PROTOCOL	180
CLINICAL SERIES	180
DISCUSSION	181
TECHNICAL PEARLS	182
CONCLUSIONS	183
CONSENT FOR PUBLICATION	183
CONFLICT OF INTEREST	183
ACKNOWLEDGEMENTS	183
REFERENCES	183
CHAPTER 12 FULL ENDOSCOPIC ANTERIOR CERVICAL DECOMPRESSION & FUSION WITH ILIAC CREST DOWEL GRAFT	185
<i>Stefan Hellinger</i>	
INTRODUCTION	185
HISTORICAL CONSIDERATIONS	186
THE OBJECTIVE	187
SURGICAL CONCEPTS	188
PROCEDURAL STEPS	188
DISCUSSION	194
CONCLUSION	195
CONSENT FOR PUBLICATION	195
CONFLICT OF INTEREST	195
ACKNOWLEDGEMENTS	195
REFERENCES	195
CHAPTER 13 PERCUTANEOUS ENDOSCOPICALLY ASSISTED CERVICAL FACET REDUCTION	200
<i>Xifeng Zhang, Zhu Zexing and Jiang Hongzhen</i>	
INTRODUCTION	200
AN EXEMPLARY CASE	202
ENDOSCOPIC DECOMPRESSION & REDUCTION	203
DEFINITIVE STABILIZATION	203
DISCUSSION	204
CONCLUSIONS	205
CONSENT FOR PUBLICATION	205
CONFLICT OF INTEREST	205
ACKNOWLEDGEMENTS	205
REFERENCES	205

CHAPTER 14 ENDOSCOPICALLY ASSISTED MINIMALLY INVASIVE LAMINOPLASTY IN THE TREATMENT OF CERVICAL SPONDYLOTIC MYELOPATHY	209
<i>Xifeng Zhang, Li Dongzhe and Jiang Hongzhen</i>	
INTRODUCTION	209
CASE INTRODUCTION	210
INDICATION FOR SURGERY & TECHNIQUE	211
CLINICAL COURSE	213
DISCUSSION	214
CONCLUSIONS	215
CONSENT FOR PUBLICATION	216
CONFLICT OF INTEREST	216
ACKNOWLEDGEMENTS	216
REFERENCES	216
CHAPTER 15 A CASE SERIES REPORT OF ENDOSCOPIC DEBRIDEMENT AND PLACEMENT OF AN INTRALESIONAL CATHETER FOR CHEMOTHERAPY OF CERVICAL TUBERCULOSIS	219
<i>Xifeng Zhang, Bu Rongqiang, Yuan Heng and Jiang Hongzhen</i>	
INTRODUCTION	219
CASE 1	220
CASE 2	222
CASE 3	224
DISCUSSION	226
CONCLUSIONS	228
CONSENT FOR PUBLICATION	228
CONFLICT OF INTEREST	228
ACKNOWLEDGEMENTS	229
REFERENCES	229
CHAPTER 16 CERVICAL ENDOSCOPIC SPINAL SURGERY: SEQUELA, FAILURE TO CURE, COMPLICATIONS AND THEIR MANAGEMENT	230
<i>Kai-Uwe Lewandrowski, Xi Jiancheng, Zheng Zeze, Wang Yipeng, Li Jinlong, Jiang Hongzhen, Stefan Hellinger and Hyeun Sung Kim</i>	
INTROCUION	231
THE REFERENCES STANDARDS	231
ACCESS & WOUND PROBLEMS	233
SEQUALAE	233
RECURRENT LARYNGEAL NERVE	234
DURAL LEAK	236
INCOMPLETE DECOMPRESSION & FAILURE TO CURE	237
VASCULAR INJURY	239
SPINAL CORD INJURY	244
CONCLUSIONS	247
CONSENT FOR PUBLICATION	247
CONFLICT OF INTEREST	247
ACKNOWLEDGEMENTS	247
REFERENCES	247
SUBJECT INDEX	476

PREFACE

Endoscopic surgery of the cervical spine is gaining increasing traction among minimally invasive spinal surgeons. Technology advances with improved miniaturized optical- and surgical access systems have purported expansion of endoscopic minimally invasive spinal surgery techniques into the cervical spine. However, many spine surgeons still hesitate to treat common painful conditions of the cervical spine with endoscopic procedures. The high risk of neurologic- and vascular injury is of concern to many of them. Additionally, damage to the trachea, esophagus, or the recurrent laryngeal nerve may put the patient at significant risk for the deleterious postoperative course. Nevertheless, increased acceptance of endoscopy by traditionally trained spine surgeons in other areas of the spine coupled with more widely available training events and unanswered patient demand has reenergized spine surgeons' interest in the endoscopic platform for the cervical spine.

The editors have come together to develop a multi-authored and clinically focused medical monograph entitled *Contemporary Endoscopic Spine Surgery: Cervical Spine* to give the reader a most up-to-date snapshot of the current state-of-the-art of cervical spinal endoscopic surgeries. The publication is intended for Orthopedic Spine & Neurosurgeons interested in treating common painful conditions including herniated disc, stenosis, tumor, and infection with minimally invasive endoscopic techniques. A wide array of highly timely and clinically relevant topics have been assembled for this purpose. They range from suitable anesthesia protocols, patient selection algorithms for anterior versus posterior cervical endoscopic decompression, clinical decision-making strategies, indications, and outcomes for endoscopically visualized cervical rhizotomy to more advanced endoscopic techniques, including complex endoscopic decompression techniques for cervical spondylotic myelopathy and other intricate procedures such as pediculotomy, vertebrectomy, and fusion.

The selection of chapters was based on contemporary trends in endoscopic cervical spine surgery. The editors recognize that this trend is based on the need for less costly yet safe and efficient solutions for the cervical spine's common degenerative conditions. Patients and other stakeholders in the ongoing debate on better value-based spine care, including healthcare policymakers and payors, are demanding of spine surgeons less burdensome and less risky treatments with shorter time to recovery, return to work, and social reintegration following spine surgery. *Contemporary Endoscopic Spine Surgery: Cervical Spine* was written with these goals in mind. The editors hope that the readers will find it an informative knowledge resource they will continue to revert to when implementing a cervical endoscopic spinal surgery program in their practice setting.

Kai-Uwe Lewandrowski

Discipline of Anesthesiology
Faculty of Medicine of Ribeirão Preto
São Paulo
Brazil

Jorge Felipe Ramírez León

Fundación Universitaria Sanitas
Clínica Reina Sofía – Clínica Colsanitas

Centro de Columna – Cirugía Mínima Invasiva
Bogotá, D.C.
Colombia

Anthony Yeung
University of New Mexico
School of Medicine
Albuquerque
New Mexico

Hyeun-Sung Kim
Department of Neurosurgery
Nanoori Gangnam Hospital
Seoul
Republic of Korea

Xifeng Zhang
Department of Orthopedics
First Medical Center
PLA General Hospital
Beijing 100853
China

Gun Choi
Neurosurgeon and Minimally Invasive Spine Surgeon
President Pohang Wooridul Hospital
South Korea

Stefan Hellinger
Department of Orthopedic Surgery
Arabellaklinik
Munich
Germany

Álvaro Dowling
Endoscopic Spine Clinic
Chile

List of Contributors

Anthony Yeung	University of New Mexico School of Medicine, Albuquerque, New Mexico Desert Institute for Spine Care, Phoenix, AZ, USA
Álvaro Dowling	Endoscopic Spine Clinic, Santiago, Chile Department of Orthopaedic Surgery, USP, Ribeirão Preto, Brazil
Bu Rongqiang	Department of Orthopedics, First Medical Center, PLA General Hospital, Beijing 100853, China
Carolina Ramírez Martínez	Minimally Invasive Spine Center for Latinamerican Endoscopic Spine Surgeons, LESS Invasiva Academy, Bogotá, D.C., Colombia
Catherine Ann Cameron	University of British Columbia, Vancouver, BC & University of New Brunswick, Fredericton, NB, Canada
Cindy Lau	Independent Scholar based in Hong Kong
Enrique Osorio Fonseca	Universidad El Bosque, Bogotá, D.C., Colombia
Gabriel Oswaldo Alonso Cuéllar	Minimally Invasive Spine Center for Latinamerican Endoscopic Spine Surgeons, LESS Invasiva Academy, Bogotá, D.C., Colombia
Hyeun Sung Kim	Department of Neurosurgery, Nanoori Gangnam Hospital, Seoul, South Korea A President of the Korean Research Society of the Endoscopic Spine Surgery (KOSSESS), South Korea A Faculty of the KOREAN Minimally Invasive Spine Surgery Society (KOMISS), South Korea A Chairman of the Nanoori Hospital Group Scientific Team, South Korea An Adjunct Professor of the Medical College of the Chosun University, Gwangju, South Korea
Il-Tae Jang	Department of Neurosurgery, Nanoori Gangnam Hospital, Seoul, Republic of Korea, Beijing 100048, China
Jin-Sung Kim	Spine Center, Department of Neurosurgery, Seoul St. Mary's Hospital, College of Medicine, The Catholic University of Korea, 222 Banpo Daero, Seocho-gu, Seoul, 137-701, Korea
João Abrão	Discipline of Anesthesiology, Faculty of Medicine of Ribeirão Preto, University of São Paulo, São Paulo, Brazil
Julia Gillen	Department of Linguistics and English Language, Lancaster University, Lancaster, UK
Jun-Song Yang	Department of Spinal Surgery, Hong-Hui Hospital, Medical College of Xi'an Jiaotong University, Xi'an, China
Jorge Felipe Ramírez León	Minimally Invasive Spine Center for Latinamerican Endoscopic Spine Surgeons, LESS Invasiva Academy, Bogotá, D.C., Colombia Fundación Universitaria Sanitas, Bogotá, D.C., Colombia
José Gabriel Rugeles Ortiz	Minimally Invasive Spine Center for Latinamerican Endoscopic Spine Surgeons, LESS Invasiva Academy, Bogotá, D.C., Colombia

Jorge Felipe Ramírez León	Minimally Invasive Spine Center for Latinamerican Endoscopic Spine Surgeons, Bogotá, D.C., Colombia Universidad El Bosque, Bogotá, D.C., Colombia
José Gabriel Rugeles Ortiz	Minimally Invasive Spine Center for Latinamerican Endoscopic Spine Surgeons, LESS Invasiva Academy, Bogotá, D.C., Colombia
Jiang Hongzhen	Minimally Invasive Spinal Surgery, Beijing Yuhe Integrated Traditional Chinese and Western Medicine Rehabilitation Hospital, Beijing 100853, China
Kai-Uwe Lewandrowski	Center for Advanced Spine Care of Southern Arizona and Surgical Institute of Tucson, Tucson, AZ, USA Department of Orthopaedic Surgery, UNIRIO, Rio de Janeiro, Brazil Department of Orthopaedic Surgery, Fundación Universitaria Sanitas, Bogotá, D.C., Colombia, USA Center for Advanced Spine Care of Southern Arizona and Surgical Institute of Tucson, Tucson, AZ, USA
Lei Chu	Department of Orthopaedics, the Second Affiliated Hospital, Chongqing Medical University, Chongqing, China
Liang Chen	Department of Orthopaedics, the Second Affiliated Hospital, Chongqing Medical University, Chongqing, China
Liu Yan-kang	Shanxi Medical University, Taiyuan 030001, China Center for Advanced Spine Care of Southern Arizona and Surgical Institute of Tucson, Tucson, AZ, USA
Li Dongzhe	Department of Orthopedics, First Medical Center, PLA General Hospital, Beijing 100853, China
Li Jinlong	Department of Orthopedics, The Eighth Medical Center, PLA General Hospital, 100091 Beijing, China
Malcolm Pestonji	Mahatma Gandhi Memorial University of Health Sciences, Navi Mumbai, Kamothe Maharashtra, India
Nicolás Prada Ramírez	Minimally Invasive Spine Center for Latinamerican Endoscopic Spine Surgeons, LESS Invasiva Academy, Bogotá, D.C., Colombia Colombia Clínica Foscal, Bucaramanga, Colombia
Nora Didkowsky	Independent Scholar based in Canada and Switzerland
Pang Hung Wu	Department of Neurosurgery, Nanoori Gangnam Hospital, Seoul, Republic of Korea Departments of Orthopaedic Surgery, National University Health System, Jurong Health Campus, Singapore
Stefan Hellinger	Department of Orthopedic and Spine Surgery, Arabellaklinik, Munich, Germany
Wang Yipeng	Department of Orthopedics, The Eighth Medical Center, PLA General Hospital, 100091 Beijing, China
Xi Jiancheng	Department of Orthopaedic Surgery, UNIRIO, Rio de Janeiro, Brazil
Yan Yu-qi	Minimally Invasive Spinal Surgery, Beijing Yuhe Integrated Traditional Chinese and Western Medicine Rehabilitation Hospital, Beijing 100039, China

Yuan Heng	Shanxi Medical University, Taiyuan 030001, China
Zhong-Liang Deng	Department of Orthopaedics, the Second Affiliated Hospital, Chongqing Medical University, Chongqing, China
Zhang Xi-feng	Department of Orthopedics, First Medical Center, PLA General Hospital, Beijing 100853, China
Zhang Lei-ming	Department of Neurosurgery, the Sixth Medical Center, PLA General Hospital, Beijing 100048, China
Zhu Zexing	Department of Orthopedics, First Medical Center, PLA General Hospital, Beijing 100853, China
Zheng Zeze	Department of Orthopedics, The Eighth Medical Center, PLA General Hospital, 100091 Beijing, China

CHAPTER 1

Cervical Endoscopy: Historical Perspectives, Present & Future

Kai-Uwe Lewandrowski^{1,2,3,*}, Jin-Sung Kim⁴, Stefan Hellinger⁵ and Anthony Yeung^{6,7}

¹ Center for Advanced Spine Care of Southern Arizona and Surgical Institute of Tucson, Tucson, AZ, USA

² Department of Orthopaedic Surgery, UNIRIO, Rio de Janeiro, Brazil

³ Department of Orthopaedic Surgery, Fundación Universitaria Sanitas, Bogotá, D.C., Colombia, USA

⁴ Spine Center, Department of Neurosurgery, Seoul St. Mary's Hospital, College of Medicine, The Catholic University of Korea, 222 Banpo Daero, Seocho-gu, Seoul, 137-701, Korea

⁵ Department of Orthopedic and Spine Surgery, Arabellaklinik, Munich, Germany

⁶ University of New Mexico School of Medicine, Albuquerque, New Mexico

⁷ Desert Institute for Spine Care, Phoenix, AZ, USA

Abstract: Endoscopy of the cervical spine traditionally has been slow to adopt. Initially, spinal endoscopy concentrated on common painful degenerative conditions of the lumbar spine, for which many of the technology breakthroughs were developed. Many of them were validated for defined clinical indications, such as a herniated disc. Stenosis applications followed later as improvements in the endoscopic platform permitted. Cervical spine application of endoscopic surgery commenced around interventional pain management with lasers and radiofrequency to improve their reliability by directly visualizing the painful pathology. Later, anterior cervical discectomies and posterior cervical foraminotomies were performed as endoscopic power burrs, and rongeurs made them possible. The most skilled surgeons moved on to perform anterior and posterior cervical spinal cord decompressions and anterior column reconstructions endoscopically further to take advantage of the potential of this platform so they could transform the traditional surgical treatments from inpatient to outpatient by performing them in a simplified manner in ambulatory surgery centers where better clinical outcomes and higher patient satisfaction could be achieved. In this chapter, the authors strove to briefly illustrate this development by giving credit to the

* **Corresponding author Kai-Uwe Lewandrowski:** Center for Advanced Spine Care of Southern Arizona and Surgical Institute of Tucson, Tucson, AZ, USA, Department of Orthopaedic Surgery, UNIRIO, Rio de Janeiro, Brazil and Department of Orthopaedic Surgery, Fundación Universitaria Sanitas, Bogotá, D.C., Colombia, USA; Tel: +1 520 204-1495; Fax: +1 623 218-1215; E-mail: business@tucsonspine.com

Kai-Uwe Lewandrowski, Jorge Felipe Ramírez León, Anthony Yeung, Hyeun-Sung Kim, Xifeng Zhang, Gun Choi, Stefan Hellinger and Álvaro Dowling (Eds.)
All rights reserved-© 2021 Bentham Science Publishers

most prominent pioneers of this fast-moving field and by setting the stage for what the reader is about to discover in this most-up-to date publication entitled: *Contemporary Spinal Endoscopy: Cervical Spine*.

Keywords: Cervical spine, Decompression, Degeneration, Disc herniation, Endoscopic, Historical considerations, Impingement, Lasers, Minimally invasive, Open, Radiofrequency, Stenosis.

INTRODUCTION

Endoscopic Spinal Surgery is rapidly becoming more mainstream [1]. Most of the clinical trials published in the last two years have focused on lumbar endoscopy. [1 - 97] Cervical endoscopic surgery is done well by far fewer surgeons, as it requires a more advanced skill level due to the higher risk associated with operating near the spinal cord [9, 44, 46, 48, 98 - 115]. It perhaps is riskier than lumbar or even thoracic endoscopic spinal surgery due to potential for life-threatening vascular injury, tracheal- or esophageal perforation, or grave neurological deficits from the spinal cord damage [116 - 119]. However, there is increased activity in that area just within the last year [9, 44, 46, 48, 98 - 104]. For this reason, the editors of *Contemporary Endoscopic Spinal Surgery: Cervical Spine* have decided to dedicate an entire volume to it as we expected an expansion of clinical indications for cervical endoscopic surgery due to technological advancements [98, 99, 111, 113] and more formalized surgeon postgraduate education programs [5, 9, 120 - 122]. There already is an increasing trend by program directors to include spinal endoscopy into residency- and fellowship programs [122]. Understanding the past, however, and recognizing preceding key opinion leaders for their contributions to the advancement of the cervical spinal endoscopy field is the basis of defining the future in terms of evolving clinical indications, understanding and mitigating risks, incorporating technology advancements into day-to-day clinical practice in a meaningful way [67], so they improve patient outcomes, and safety, and prove to be cost-effective. Therefore, this team of authors came together to help the novice spine surgeon maneuver this fast-moving subspecialty.

RECYCLED TRENDS

Many historical perspectives have been revisited by repurposing existing technologies in new surgical approaches. Likewise, have we witnessed the resurgence of previously employed surgical techniques that have been applied in the early years of spinal endoscopy. As in the fashion industry, where certain trends reappear in a modernized form by fusing different design elements or materials to create new products and marketing strategies, spine surgeons are

similarly susceptible to embracing modern trends in spinal endoscopy in their quest to overcome shortcomings of existing treatment protocols for common degenerative conditions of the cervical spine. Industry recycles existing medical know-how and often modernizes them by technology transfer from other commercial areas, such as the aerospace or the automotive industry, by innovation mechanisms of adoption, miniaturizations, automation, and system integration to develop advanced surgical techniques, instruments-, and equipment of improved performance, reliability, and durability. Innovations widely adopted in other industries are making their way into medical applications [123]. Examples include miniaturized high-definition (HD) video technology with touch-screen displays, high-speed HD recording equipment [124, 125] robotics- [126 - 131] and navigation tools [132 - 134], and 3D heads-up display goggles [9] for surgeons to be worn during surgery to improve eye-hand coordination and many others. Rapid endoscopic spine surgery product development with a myriad of instruments being pushed by an army of salespeople is another area of rapid change that has been playing itself out in the operating room — endoscopes with larger inner working channels, sturdy enough to withstand the abuse of more frequent short sterilization cycles to respond to the rising caseload, motorized shavers, drills, and large Ø rongeurs employed for rapid decompression [24, 31, 37, 38, 48].

THE CERVICAL ENDOSCOPE OF THE FUTURE

Endoscopes previously rated for 200 to 250 simple discectomy surgeries are now used in more complex and demanding advanced endoscopic procedures of the spine. These include intradiscal therapies with cool lasers [52, 135 - 139] or bipolar radiofrequency [44, 82, 140 - 143] devices for the early stages of the disease and the late stages of the disease where aggressive decompression and reconstructive procedures may be needed for spinal stenosis- and instability related neural element encroachment. Endoscopic placement of spinal implants, such as interbody fusion cages and posterior supplemental fixation with pedicle screw-rod constructs, are other examples of contemporary advancements in endoscopic spinal surgery [51, 60, 63, 77, 80, 92, 144]. This increasing quality and durability demand on spinal endoscopes to work in a large variety of surgical indication scenarios have widened the field of industry competitors with some front-runners pushing clinical product portfolios, reimbursement, and coding agendas. Traditional German endoscopic equipment makers are experiencing competition from China, Korea, and Japan by domestic Asian manufacturers whose technological know-how has now risen to a competitive level at lower manufacturing and acquisition cost with similar quality. In some cases, Asian spinal endoscopy, radiofrequency, and motorized decompression equipment has even advanced beyond what European competitors can put forward mainly

CHAPTER 2

Anesthesia for Minimally Invasive Surgery of the Cervical Spine

João Abrão¹, Kai-Uwe Lewandrowski^{2,3,4} and Álvaro Dowling^{5,6}

¹ Discipline of Anesthesiology, Faculty of Medicine of Ribeirão Preto, University of São Paulo, São Paulo, Brazil

² Center for Advanced Spine Care of Southern Arizona and Surgical Institute of Tucson, Tucson, AZ, USA

³ Department of Orthopaedic Surgery, UNIRIO, Rio de Janeiro, Brazil

⁴ Department of Orthopaedic Surgery, Fundación Universitaria Sanitas, Bogotá, D.C., Colombia, USA

⁵ Endoscopic Spine Clinic, Santiago, Chile

⁶ Department of Orthopaedic Surgery, USP, Ribeirão Preto, Brazil

Abstract: Anesthesia for the outpatient ambulatory surgery center has to be tailored to the surgery. The length of surgery, the trauma of painful dissection, and the amount of blood loss have to be considered. Outpatient spine surgery is characterized by shorter simplified versions of their inpatient counterparts carried out in a hospital setting. Many outpatient spine surgeries are minimally invasive through small incisions with less blood loss, tissue disruption, and, more importantly, less painful stimulus during surgery. These modern spine surgery versions also apply local anesthesia strategically to diminish the need for deep anesthesia. In some scenarios, the surgeon may wish to speak to the sedated yet awake patient to lower the risk of injury to neural structures when performing the more dangerous portions of the endoscopic decompression surgery. The need to communicate with the patient is undoubtedly of high relevance in the cervical spine, which requires the anesthesiologist to tailor the management of the patient's anesthesia to the surgeons' needs. The monitored anesthesia care (MAC), where sedation is achieved with various sedatives and narcotics, is most appropriate for outpatient endoscopic cervical spinal surgeries. These surgeries may be performed with the patient in supine (anterior cervical surgery) or in a prone position (posterior cervical surgery). Patients in the prone position may pose additional problems maintaining adequate ventilation and sedation while keeping the patient comfortable enough to tolerate the procedure and yet still communicating with the surgeon. In other scenarios or different surgeon preferences communicating with the patient during an outpatient endoscopic cervical surgery may not be required. A Laryngeal Mask Airway (LMA) may be more appropriate with the patient in a prone position. This chapter describes

* **Corresponding author Álvaro Dowling:** Orthopaedic Spine Surgeon, Director of Endoscopic Spine Clinic, Santiago, Chile, Visiting Professor, Department of Orthopaedic Surgery, USP, Ribeirão Preto, Brazil; Tel: +56 9 6227 1201; E-mail: alrodomo@gmail.com

modern MAC concepts, airway management in the supine and prone position, and sedatives as it applies to cervical endoscopic spinal surgery in an ambulatory surgery center.

Keywords: Balanced Anesthesia, Cervical Spine Endoscopy, Monitored Anesthesia Care.

INTRODUCTION

Open spine surgery is increasingly replaced by Minimally Invasive Spine Surgery (MISS). Nowadays, MISS is the technique of choice in treating common degenerative conditions of the cervical spine [1 - 3]. The main indication for MISS is the cervical herniated intervertebral disc [1 - 6]. The minimal tissue trauma, reduced blood loss, decreased postoperative pain, and a diminished need for deep anesthesia have been recognized as significant advantages [5, 7, 8]. Many patients experience a much shorter length of inpatient stay [9]. In endoscopic spine surgery, light sedation monitored anesthesia care is the critical element in allowing patients to discharge early from the recovery room or the ambulatory surgery center (ASC) [9, 10].

In this chapter, the authors attempt to describe their methodology of providing anesthesia tailored to the outpatient endoscopic cervical decompression surgery, where patients need minimal amounts of sedatives and narcotics to feel comfortable throughout different stages of the cervical endoscopy. The surgeon also heavily relies on the patient's verbalization ability during the procedure. The awake patient able to speak during operation with the surgeon is the most reliable and best monitoring of the patient's neurological function during this delicate and potentially dangerous procedure. Surgeons and anesthesiologists need to communicate closely to tailor the anesthesia to support the surgeon's needs so the cervical surgery can be executed safely, efficiently, and timely. This chapter is as much about this communication between surgeon and anesthesiologist as it is about the actual anesthesia protocols described herein.

ANESTHESIA STRATEGIES

In general, recovery from anesthesia and surgery is faster when patients can be sent home with higher patient satisfaction. Considering the authors intend to demystify the belief that spinal surgery is a complicated procedure, we stipulate that the patient should not be admitted to a hospital. However, there are several concerns with this stipulation. First, the majority of cervical spine endoscopies are posterior procedures. They seem preferred by most endoscopic spine surgeons for greater versatility, simplicity, and less risk to the vital structures in the neck. Posterior procedures are done, though, with the patient in the prone position. Most

anesthesiologists prefer endotracheal intubation and general anesthesia to secure the airway. While endotracheal intubation with general anesthesia is helpful in quickly correcting intraoperative respiratory depression or even maintain the patient's mechanical ventilation should the patient cease to breathe spontaneously under overzealous use of sedation or anesthesia, it certainly prolongs the postoperative recovery. Second, general anesthesia may lead to other postoperative problems, including prolonged wakeup, urinary retention with the need for catheterization in the recovery room, cardiopulmonary compromise, constipation, *etc.* Hence, posterior and anterior endoscopic cervical spine surgeries are preferably carried out in an ambulatory surgery center with local anesthesia with sedation. Endoscopic surgery in awake patients minimizes the risk of neural injury. Moreover, this monitored anesthesia care streamlines wake up and recovery. It improves workflow. The authors' experience is that general anesthesia is unnecessary for many patients who undergo ambulatory surgeries. Still, it may be advisable in some patients with medical comorbidities requiring complex endoscopic decompression. This team of authors typically decides for conscious sedation under monitored anesthesia care (MAC) whenever possible [10, 11]. To achieve the right sedation level and comfort in the patient undergoing cervical endoscopy, the anesthesiologist has to perceive and anticipate situations where the patient may feel severe pain and needs to be responsive and cooperative. Since the surgeon may concentrate on the operation, the anesthesiologists should also assess his monitors' stimulation level.

SEDATION

There are many scales to quantify the sedation grade. The most popular amongst anesthesiologists is the Ramsay Sedation Scale (Table 1) [12-17]. Following this scale, our target is level 3. The patient can still recognize the manipulation of the spinal nerve by touch while reasonably being able to tolerate the pain and even follow commands. The ventilation is adequate at this level, and typically only a supplementary oxygen nasal cannula is needed. Sometimes after introducing the dilators to place the endoscopic working cannula, the surgeon wants to check the neurological status by asking the patient to move his feet. Ramsay stage 3 is the ideal sedation level to accomplish cooperation from the patient. The question of the perfect sedative is of particular significance. The properties of such a perfect sedative are listed in Table 2. All the pharmacokinetics and pharmacodynamic characteristics have to be considered when choosing a drug for the MAC.

Table 1. Ramsay Sedation Scale.

Definition	Score
Patient is anxious and agitated or restless, or both	1

CHAPTER 3

Algorithms to Choose Between Anterior and Posterior Cervical Endoscopy

Álvaro Dowling^{1,2}, Kai-Uwe Lewandrowski^{3,4,5,*} and Helton Delfino⁶

¹ Endoscopic Spine Clinic, Santiago, Chile

² Department of Orthopaedic Surgery, USP, Ribeirão Preto, Brazil

³ Center for Advanced Spine Care of Southern Arizona and Surgical Institute of Tucson, Tucson, AZ, USA

⁴ Department of Orthopaedic Surgery, UNIRIO, Rio de Janeiro, Brazil

⁵ Department of Orthopaedic Surgery, Fundación Universitaria Sanitas, Bogotá, D.C., Colombia, USA

⁶ Department of Orthopaedic and Anesthesiology, Ribeirão Preto Medical School, University of São Paulo, São Paulo, Brazil

Abstract: Full endoscopic surgery of the cervical spine has gained more popularity, raising the question of its indications, patient selection criteria, and the appropriate choice of the various anterior and posterior techniques. In this chapter, the authors attempt to delineate the criteria for selecting patients for the different full endoscopic surgical techniques for the cervical spine's common painful degenerative conditions. The authors review the common forms of surgical pathology, including foraminal, lateral- and central canal stenosis, and distinguish between radiculopathy and myelopathy. They introduce algorithms for the full endoscopic treatment of these conditions by relying on validated classification systems for cervical disc herniations and their associated appearance on advanced imaging studies, including magnetic resonance imaging and computed tomography. Moreover, the authors review the risks, contraindications, and limitations of the various anterior and posterior full endoscopic surgery techniques related to the current technology standards.

Keywords: Anterior and posterior approaches, Cervical foraminal and central stenosis, Cervical herniated disc, Full endoscopy, Indications, Limitations.

* **Corresponding author Kai-Uwe Lewandrowski:** Center for Advanced Spine Care of Southern Arizona and Surgical Institute of Tucson, Tucson, AZ, USA, Department of Orthopaedic Surgery, UNIRIO, Rio de Janeiro, Brazil and Department of Orthopaedic Surgery, Fundación Universitaria Sanitas, Bogotá, D.C., Colombia, USA; Tel: +1 520 204-1495; Fax: +1 623 218-1215; E-mail: business@tucsonspine.com

Kai-Uwe Lewandrowski, Jorge Felipe Ramírez León, Anthony Yeung, Hyeun-Sung Kim, Xifeng Zhang, Gun Choi, Stefan Hellinger and Álvaro Dowling (Eds.)

All rights reserved-© 2021 Bentham Science Publishers

INTRODUCTION

Innovative technology and techniques have revolutionized the minimally invasive spine (MIS) surgery of the lumbar spine [1 - 12]. Cervical pathologies present with different anatomical problems, indications, and risks [13 - 17]. MIS applications have gained some traction in posterior cervical spine surgeries [18 - 22], but endoscopic surgery has taken longer to garner support in the cervical spine [23 - 29]. The smaller working space, proximity to vital structures, and the potentially high-risk nature of operating on compressive pathology affecting the spinal cord and the exiting nerve roots [15, 17]. Anterior cervical approaches can be complicated by injury to the great vessels, dysphagia, and phonation problems [13]. Posterior approaches can result in severe postoperative neck pain from muscular dissection and delayed iatrogenic deformities and instability [30, 31]. Consideration of fusion and non-fusion procedures also play a critical role in surgical decision making of MIS cervical MIS options [32 - 35]. Despite these potential problems, advances in MIS surgery for common cervical pathologies have gained traction in recently with many peer-reviewed articles having been published within the last year alone [21, 23, 25, 36 - 44].

Anterior endoscopic approaches have been employed to treat soft hernias, axillary stenosis due to uncovertebral hypertrophy, and central decompression and fusion for endstage degenerative disc disease, instability, and spinal cord compression [38, 39, 42, 44 - 46]. Posterior endoscopic approaches were practical for decompressive laminotomy and foraminotomy in treating lateral cervical canal stenosis and paramedial hernias [27, 43, 46, 47]. Advances in spinal instrumentation have permitted to replace traditional lateral mass screw and rod constructs with percutaneous facet screws, further facilitating the application of MIS techniques in the cervical spine [48, 49]. Advanced surgeon training and refined skill level, as well as enhanced understanding of the indications and outcomes with endoscopic cervical spinal surgery, have let to an increase in these procedures, as reflected by the number of recent peer-reviewed publications being on the rise [50]. In the following, we describe an algorithm for the best choice of these novel endoscopic surgery techniques to treat the cervical spine's common degenerative conditions. Classification of the compressive pathology to be treated is an appropriate way to build an algorithm for the optimum choice of anterior *versus* posterior full endoscopic approach to the cervical spine. However, as with most surgical procedures, algorithms, while complying with many evidence-based concepts, it is becoming more critical to depend on not just on safety, cost-effectiveness, and the concept, but as a surgical procedure, the surgeon factor and the surgical skill of each individual surgeon is the big variable that cannot be defined by algorithms. Therefore, the authors of this chapter ask the prospective endoscopic spine surgeon take their own training and skill level into account

when attempting to perform these full endoscopic procedures in the cervical spine.

HERNIATED DISC

The level and the location of the herniated disc in the disease cervical motion segment is a critical consideration. Secondary considerations relate to whether the disc herniation is soft or calcified as different endoscopic instruments and procedural steps may be required for these calcified herniations. The retraction of cervical nerve roots and the spinal cord may be less practical and is best avoided. The inability to retract these sensitive neural elements dictates surgical exposure and approaches in particular with central disc herniations at the C4/5 level, where the risk for the neurological deficit is the highest – patients may develop a postoperative C5 nerve palsy, which is by far the most commonly reported neurological complication with cervical spine surgery in general [45]. In comparison, a paramedian disc herniation may be decompressed by both approaches. Absolute and relative contraindications to spinal endoscopy applications in the cervical spine may exist in some individual or particular situations. For example, the anterior approach may be contraindicated in collapsed disc spaces where the disc height is less than 4 mm, making the introduction of the endoscopic working cannula virtually impossible with most current systems. Another example is a large anterior vertebral osteophyte or discal calcification. Also, cases involving substantial craniocaudal disc sequestration may be a complete contraindication to anterior cervical endoscopic discectomy (ACED) because of a high likelihood of causing iatrogenic injury to the spinal cord. This team of authors routinely employs the criteria of the Odom classification of cervical herniated disc when stratifying patients for endoscopic discectomy surgery (Table 1) [51 - 54] Exemplary intraoperative images of PECD and AECD are shown in Fig. (1).

Table 1. Types of cervical disc herniations as defined by the Odom classification [54].

Odom Classification	
Type I	Unilateral soft disc protrusion with nerve root compression
Type II	Foraminal spur or hard disc with nerve root compression
Type III	Medial soft disc protrusion with spinal root compression
Type IV	Transverse ridge or cervical spondylosis with spinal cord compression

CHAPTER 4

Contemporary Clinical Decision Making in Full Endoscopic Cervical Spine Surgery

Álvaro Dowling^{1,2}, Kai-Uwe Lewandrowski^{3,4,5,*} and Helton Delfino⁶

¹ Endoscopic Spine Clinic, Santiago, Chile

² Department of Orthopaedic Surgery, USP, Ribeirão Preto, Brazil

³ Center for Advanced Spine Care of Southern Arizona and Surgical Institute of Tucson, Tucson, AZ, USA

⁴ Department of Orthopaedic Surgery, UNIRIO, Rio de Janeiro, Brazil

⁵ Department of Orthopaedic Surgery, Fundación Universitaria Sanitas, Bogotá, D.C., Colombia, USA

⁶ Department of Orthopaedic and Anesthesiology, Ribeirão Preto Medical School, University of São Paulo, São Paulo, Brazil

Abstract: Full endoscopic surgery of the cervical spine is done in select centers where the clinical and surgical expertise is high. The procedure can be potentially dangerous in less well-trained hands, with the prospect of damage to vital vascular structures, and injury to the trachea, esophagus, cervical nerve roots, and the spinal cord. Also, cervical endoscopy is competing with traditional spinal surgeries, such as anterior cervical discectomy and fusion, or posterior cervical foraminotomy, whose clinical outcomes are reliably favorable. Therefore, most surgeons have a hard time replacing their well-performing anterior- or posterior cervical surgeries that they may very well be carrying out through open or mini-open incision or other forms of minimally invasive spinal surgery techniques. Patient satisfaction with these procedures is generally very high, and the complication rate is relatively low, and their management is well-understood. Again, is there a need for change? It is apparent that to the innovators, the answer to this question is obviously “yes” because they are looking for practical, yet less burdensome, lower cost, and more simplified outpatient cervical spine surgeries. The general push by payors and patients to transition spine care from in- to outpatient setting requires spine surgeons to rethink their approach to treating common degenerative conditions of the cervical spine. New algorithms based on updated classification systems and clinical outcome analysis of contemporary surgical techniques are required to make this transition feasible. In this chapter, the authors illustrate the application of full-endoscopic cervical spine surgery techniques, review-

* **Corresponding author Kai-Uwe Lewandrowski:** Center for Advanced Spine Care of Southern Arizona and Surgical Institute of Tucson, Tucson, AZ, USA, Department of Orthopaedic Surgery, UNIRIO, Rio de Janeiro, Brazil and Department of Orthopaedic Surgery, Fundación Universitaria Sanitas, Bogotá, D.C., Colombia, USA; Tel: +1 520 204-1495; Fax: +1 623 218-1215; E-mail: business@tucsonspine.com

wing their indications, and the clinical decision-making by discussing the rationale for the procedure of choice selection ranging from patient criteria, anatomical considerations, surgeon training-, and skill level. This chapter is intended to serve as a guide for the established spine surgeons who are yet inexperienced with endoscopy and evaluates whether full endoscopy of the cervical spine should be in their armamentarium.

Keywords: Cervical endoscopy, Cervical herniated disc, Cervical stenosis, Clinical decision making algorithms, Myelopathy.

INTRODUCTION

In recent years, many spine surgeons have begun to perform decompression procedures and hernia removal by cervical endoscopy, mainly through the posterior approach. Some publications show that posterior foraminotomy has similar results to open traditional anterior cervical discectomy and fusion (ACDF) with the difference of having a lower cost [1, 2] but slightly higher reoperation rate [3]. On the other hand, with endoscopic techniques, one-level myelopathies began to be treated with over-the-top techniques, mainly due to the improvement of the microendoscopic Kerrison increase working channels size, and better drillings of high speed, allowing generally faster decompression central canal [4]. Traditional cervical management includes posterior cervical foraminotomy and anterior cervical discectomy and fusion (ACDF). Those procedures are exhaustively validated. However, patients may develop recurrent symptoms in some cases due to progression of the underlying degenerative disease process with vertical collapse and loss of disc height, and increasing foraminal and central stenosis, particularly at other adjacent levels. This dynamic is known as classic adjacent segment disease or “transition syndrome”. It sometimes prompts additional surgeries in the future. Nowadays, technological advances have allowed us to achieve similar clinical outcomes with shorter, more simplified surgeries through smaller incisions and less bleeding and less postoperative pain than with traditional surgery [5].

In our centers, we have performed endoscopically assisted minimally invasive cervical spine surgery for more than 15 years employing posterior foraminotomy techniques. From 2004-2010, a retrospective study was conducted on 123 Patients undergoing posterior endoscopic cervical foraminotomy (PECF) for unilateral foraminal soft and hard disc disease with or without concomitant foraminal stenosis. All patient present radicular pain at least for 3 months with an average of 7 month and follow up at least 24 months. Our results show 90% excellent or good in the Neck Disability Index (NDI) [6]. Also Visual Analogue Scale (VAS) decrease significantly after surgery. By improving the full endoscopic technology to perform the foraminotomy faster and safer, achieving the same goal than the

other endoscopic assisted technique, we gradually changed the method [7, 8]. With the advent of technology advances, patient selection criteria changed, and the indications for minimally invasive posterior cervical surgery have expanded [8]. One of the most significant advantages of minimally invasive surgery (MIS) using endoscopy is the minimal muscle dissection needed to access the spine (Fig. 1). Additional advantages of MIS include reduced both operative pain and disability, decreased blood loss and soft tissue disruption, reduced surgical time and the ability to perform these surgeries in outpatient setting often under sedation and local rather than general anesthesia. The latter is of significance to most patients who now actively seek out surgeons that offering these services.

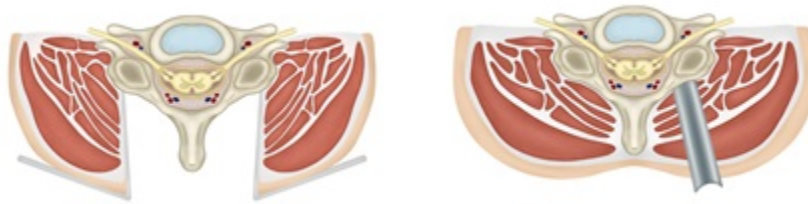

Fig. (1). Comparison of open cervical spine surgery to endoscopic cervical surgery. From left to right, **(a)** The amount of bone exposure and soft-tissue disruption is significantly bigger in open procedures in comparison to **(b)** endoscopic surgery, in which a working cannula reaches the surgical point without much tissue damage.

It is clear that this recent expansion of surgical indications has largely hinged on several other factors, implementation of higher definition video technology, as well as advances in the endoscopes instrumentation including working cannulas, irrigations systems, drills, Kerrisons and other rongeurs and chisels to afford more sophisticated bony decompression of neural elements with better visualization [2]. In this chapter, we will briefly review the different approaches to endoscopic surgery of the cervical spine. We will emphasize the use of clinical classification systems for stenosis and the type and localization of herniated disc and will discuss how to best approach compressive pathology in the anterior, posterior, or lateral spinal canal or the cervical foramina and how it relates to the best application of full endoscopic spinal surgery techniques including anterior endoscopic cervical discectomy (AECD), anterior endoscopic cervical foraminotomy (AECF), posterior endoscopic cervical discectomy (PECD) and other endoscopically assisted techniques which may appear more appropriate for cases with more severe stenosis of the cervical spinal canal or the foramina.

CLINICAL AND RADIOGRAPHIC EVALUATION

It is important that all patients are evaluated clinically and radiologically. Clinical evaluation includes history and physical examination, neurological function, and

CHAPTER 5

Indications and Outcomes with Endoscopic Posterior Cervical Rhizotomy

Kai-Uwe Lewandrowski^{1,2,3}, Ralf Rothoerl⁴, Stefan Hellinger⁵ and Hyeun Sung Kim^{6,7,8,9,10,*}

¹ Center for Advanced Spine Care of Southern Arizona and Surgical Institute of Tucson, Tucson, AZ, USA

² Department of Orthopaedic Surgery, UNIRIO, Rio de Janeiro, Brazil

³ Department of Orthopaedic Surgery, Fundación Universitaria Sanitas, Bogotá, D.C., Colombia, USA

⁴ Department of Neurosurgery, Isar Clinic, Munich, Germany

⁵ Department of Orthopedic and Spine Surgery, Arabellaklinik, Munich, Germany

⁶ Department of Neurosurgery, Nanoori Gangnam Hospital, Seoul, Republic of Korea

⁷ A President of the Korean Research Society of the Endoscopic Spine Surgery (KOESS), South Korea

⁸ A Faculty of the Korean Minimally Invasive Spine Surgery Society (KOMISS), South Korea

⁹ A Chairman of the Nanoori Hospital Group Scientific Team, South Korea

¹⁰ An Adjunct Professor of the Medical College of the Chosun University, Gwangju, South Korea

Abstract: Axial neck pain without much radicular shoulder arm pain is a somewhat tricky situation for spine care providers. Patients often have the early-stage degenerative disease of the cervical intervertebral disc and facet joints, with minimal spinal alignment changes and without instability. Yet such patients may have legitimate symptoms and may have failed multiple rounds of physical therapy, spinal injections, activity modifications, non-steroidal anti-inflammatories, and other medical and supportive care measures. These patients may not fit traditional image-based spinal care protocols and are mostly left untreated. This chapter presents the authors' indications, and clinical outcomes with an endoscopically visualized combined mechanical and radiofrequency facet ablation with a minimal laminotomy at the symptomatic levels. They offer their rationale behind their strategies to attend to these patients with minimal cervical spine disease on advanced images but with unmanageable complaints who ordinarily have been falling into this watershed area of

* **Corresponding author Hyeun Sung Kim:** Department of Neurosurgery, Nanoori Gangnam Hospital, Seoul, Republic of Korea, A President of the Korean Research Society of the Endoscopic Spine Surgery (KOESS), South Korea, A Faculty of the Korean Minimally Invasive Spine Surgery Society (KOMISS), South Korea and A Chairman of the Nanoori Hospital Group Scientific Team, South Korea; E-mail: neurospinekim@gmail.com

Kai-Uwe Lewandrowski, Jorge Felipe Ramírez León, Anthony Yeung, Hyeun-Sung Kim, Xifeng Zhang, Gun Choi, Stefan Hellinger and Álvaro Dowling (Eds.)
All rights reserved-© 2021 Bentham Science Publishers

traditional spine care and reviewing possible pain relief mechanisms. The latter may be achieved not only by the combined mechanical and radiofrequency ablation of the cervical facet joint complex but also rely on modulation of the activity of the dorsal root ganglion of the cervical nerve root at the affected level. Outcomes are favorable in most patients, suggesting the authors' approach to treating these patients has merits; thus, warranting further clinical validation.

Keywords: Axial neck pain, Cervical spine, Decompression, Degeneration, Disc herniation, Endoscopic, Impingement, Minimally invasive, Open, Radiofrequency, Rhizotomy, Stenosis.

INTRODUCTION

Chambers *et al.* has described the cervical rhizotomy for axial neck pain. As a treatment modality as early as in 1954. Others have reported on their clinical outcomes in the 1960ies. Early on, the treatment was used to treat torticollis due to spasticity or dyskinetic syndromes of the neck [1, 2]. Initial treatments were directed at the cervical nerve roots to modulate their activity. In 1977, Fraioli *et al.* reported their results with the bilateral cervical posterior rhizotomy, which they performed in 16 dystonia and athetosis infantile cerebral palsy (CP) patients [3]. As a result of their rhizotomy procedures ranging from C1 to C6, their patients experienced a significant decrease in muscle spasms and athetoid movements, and improved posture and voluntary mobility. However, the authors also reported complications in 5 patients who suffered from uneven and irregular breathing associated with lethargy immediately postoperatively due to reduced diaphragmatic activity in 4 of these five patients. The latter four patients developed pneumonia, of which only one patient recovered. The other three of their pneumonia patients eventually died. Urinary retention for up to 3 months was also observed in 4 of the five patients. The authors concluded that the lesion of ascending reticular fibers in the posterior cervical roots could have been responsible for the observations. This early report by Fraioli *et al.* indicates that there are potentially severe side effects from cervical rhizotomy procedure when used to treat CP-related problems [3].

Later, the procedure was used to manage intractable pain in the face and cervical region caused by malignant tumors. Mracek *et al.* reported a transverse separation of the tract of the cerebral nerves V, IX, X, and VII [4]. They performed the procedure with stimulation at several levels under local anesthesia. Besides, the authors severed sensitive cervical roots 1 to 3. The authors explained that the extent of the separation should depend on the extent of the painful area and the effect of the individual separations. The authors reported reasonable pain control in 13 patients, of which 4 had laryngeal carcinomas, 2 parotid carcinomas, 2 tongue carcinomas, one carcinoma of the pharynx, 1 of the maxilla, 1 of the lip, 1

of the tonsil, and 1 of the Os occipitale, in most cases with submandibular metastases [4]. Another application of rhizotomy in treating intractable shoulder pain was demonstrated by Grunert *et al.* in 1985 [5]. Their publication entitled “Results of cervical chordotomy with and without rhizotomy in therapy-resistant pain in the shoulder and arm,” the authors reported 39 patients of theirs who they treated with the upper cervical cordotomy at the C1/C2 level. The majority of them (30 patients) were cancer patients with intractable pain of the shoulder and arm region. The remaining 9 had a benign lesion. The authors performed a simultaneous cordotomy and rhizotomy in 9 of their tumor patients and 2 patients with benign lesions. They concluded that the upper cervical cordotomy effectively reduced the pain of cancer patients whose pain cannot be controlled adequately in any other way. However, they found that the addition of the rhizotomy did not provide a further advantage [5]. Kapoor *et al.* reported on CT-guided nerve block before dorsal cervical rhizotomy they performed on 17 occipital neuralgia patients who underwent 32 C2 or C2 and C3 nerve root blocks achieving temporary pain relief [6]. The authors performed unilateral (n = 16) or bilateral (n = 1) intradural C1 (n = 9), C2 (n = 17), C3 (n = 17), or C4 (n = 7) dorsal rhizotomies. At an average final follow-up of 20 months, 11 patients (64.7%) reported complete relief, two (11.8%) had partial relief, and four (23.5%) had no relief. The authors concluded that the proper selection of patients for intradural cervical dorsal rhizotomy might produce good pain relief [6]. Gande *et al.* corroborated these findings in a long-term 14-year follow-up study of 70 patients who underwent intradural cervical dorsal root rhizotomy for refractory occipital neuralgia [7].

Less aggressive pain management applications were reported in the early 1990s. Babur *et al.* reported facet rhizotomy for cervical radiculitis in the Mount Sinai Medical Journal in 1994 [8]. They had performed 166 successful cervical facet denervations or cervical facet rhizotomies on 133 patients suffering from intractable cervical facet pain. Li *et al.* reported on endoscopic dorsal ramus rhizotomy in facetogenic chronic low back pain patients [9]. Duff *et al.* demonstrated percutaneous radiofrequency rhizotomy for cervical zygapophyseal joint mediated neck pain *via* radiofrequency (RF) rhizotomy of the medial branches of the dorsal rami from the spinal nerves [10]. These authors set out to determine the duration of complete pain relief, analgesic consumption, and any procedure-related problems. The authors found that at 12 months, 63.64% of their patients were still pain-free. The one-year follow-up time point was also the median duration of complete pain relief. Typically, these patients with pain relief stopped using prescription analgesics by six weeks after the rhizotomy procedures. The authors did not report any repeat cervical RF rhizotomies, infections, or unplanned admissions to a hospital. They concluded that percutaneous cervical RF rhizotomy is an effective treatment for cervical zygapophyseal joint mediated neck pain [10]. Radiofrequency ablation of the

CHAPTER 6

Anterior Endoscopic Cervical Discectomy

Malcolm Pestonji¹, Álvaro Dowling^{2,3}, Helton Delfino⁴ and Kai-Uwe Lewandrowski^{5,6,7}

¹ Mahatma Gandhi Memorial University of Health Sciences, Navi Mumbai, Kamothe Maharashtra, India

² Endoscopic Spine Clinic, Santiago, Chile

³ Department of Orthopaedic Surgery, USP, Ribeirão Preto, Brazil

⁴ Department of Orthopaedic and Anesthesiology, Ribeirão Preto Medical School, University of São Paulo, São Paulo, Brazil

⁵ Center for Advanced Spine Care of Southern Arizona and Surgical Institute of Tucson, Tucson, AZ, USA

⁶ Department of Orthopaedic Surgery, UNIRIO, Rio de Janeiro, Brazil

⁷ Department of Orthopaedic Surgery, Fundación Universitaria Sanitas, Bogotá, D.C., Colombia, USA

Abstract: Anterior endoscopic cervical discectomy (AECD) is a surgical procedure born in the era of minimally invasive spine surgery. A cervical discectomy through a 4 mm incision, in skilled hands, can be an ambulatory outpatient procedure where the patient may be discharged the same day from the surgical facility. Recent advances in video-endoscopic equipment and decompression tools have facilitated endoscopic spinal surgery techniques to common soft disc herniations in the cervical spine. The authors review the procedural steps of the procedure and position it as a motion preservation surgery that may alleviate radicular symptoms in the upper extremities that have not responded to non-operative care. Unrelenting arm pain in the younger patient with early degeneration of the cervical spine motion segments may be the most appropriate indication for the AECD. Procedural details and outcomes from a clinical series are reviewed to illustrate technical pearls and postoperative problems common to the procedure – with segmental kyphosis and vertical collapse of the disc space being the most relevant – if not carried out with attention to detail.

Keywords: Anatomy cervical spine, Anterior endoscopy, Cervical disc herniation.

* **Corresponding author Kai-Uwe Lewandrowski:** Center for Advanced Spine Care of Southern Arizona and Surgical Institute of Tucson, Tucson, AZ, USA, Department of Orthopaedic Surgery, UNIRIO, Rio de Janeiro, Brazil and Department of Orthopaedic Surgery, Fundación Universitaria Sanitas, Bogotá, D.C., Colombia, USA; Tel: +1 520 204-1495; Fax: +1 623 218-1215; E-mail: business@tucsonspine.com

Kai-Uwe Lewandrowski, Jorge Felipe Ramírez León, Anthony Yeung, Hyeun-Sung Kim, Xifeng Zhang, Gun Choi, Stefan Hellinger and Álvaro Dowling (Eds.)

All rights reserved-© 2021 Bentham Science Publishers

INTRODUCTION

Anterior endoscopic cervical discectomy is probably the most demanding surgery amongst all the endoscopic surgeries in the cervical spine. Knowledge of the applied surgical anatomy of the anterior cervical spine is critical to avoid injury to the vital structures which are at risk when the endoscopic working cannula is traversing the anterior neck in a path to the anterior cervical spine. Once the cervical disc spaces are approached *via* percutaneous dissection with serial dilation, the placement of the work cannula into the disc space may be difficult due to reduced disc height in segments with advanced degeneration. Anterior osteophytes or calcifications of the anterior longitudinal ligament may increase the level of difficulty with the procedure. When done in younger patients it carries the advantage of a motion preservation procedure. In this chapter, the authors review the indications, the surgical steps, the inclusion- and exclusion criteria, and postoperative care.

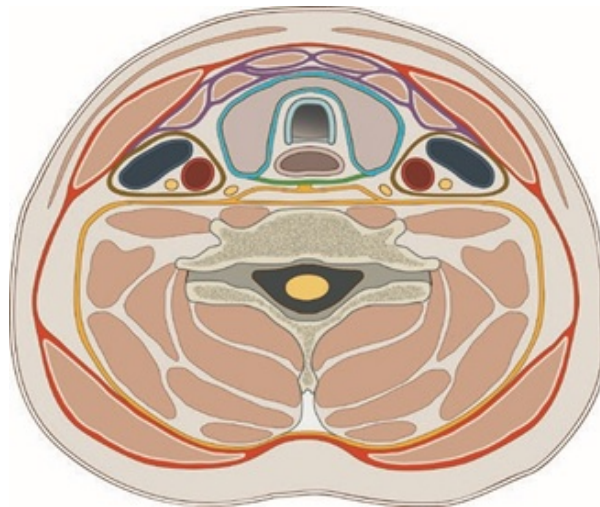


Fig. (1). Schematic drawing of the cross-section through the neck showing the cervical spinal motion segment at the C5/6 level. The turquoise line indicates the content of the tracheoesophageal groove. The purple outlines the anterior strap muscles, and the red line traces the superficial cervical muscles, *i.e.*, the platysma in the anterior cervical spine (top). The carotid sheath content is outlined on both sides by the brown line.

ANATOMICAL CONSIDERATIONS

The superficial cervical fascia is very thin and covers the platysma. The four layers of the deep cervical fascia invest the neck muscles. This fascial system is composed of fibroareolar tissue filling up the empty spaces among muscles, vessels, and the neck's viscera. This fibroareolar tissue is variable, forming thin

fascial layers or loosely arranged connective tissue matrix. It can easily be dissected. The superficial layer surrounds the sternocleidomastoid muscles uniting in the midline. The middle layer covers the strap muscles and forms a visceral fascia for the trachea, the esophagus, and the recurrent laryngeal nerve. The alar fascia is attached on both sides to this visceral fascia medially and the carotid sheaths laterally. The deep layer is the prevertebral fascia, covering the spine's anterior surface, longus colli, and scalene muscles (Figs. 5 and 2).

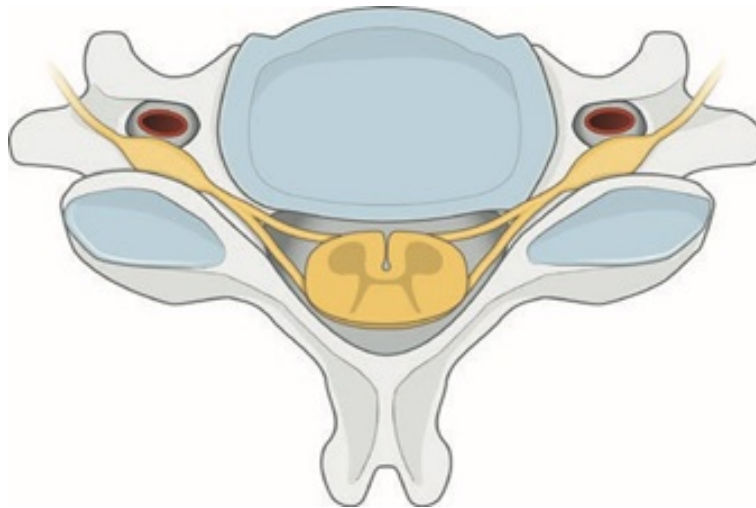


Fig. (2). Schematic drawing of the cross-section through the C5/6 level showing the spinal cord and nerve roots which in the cervical spine exit anteriorly but posteriorly to the vertebral artery.

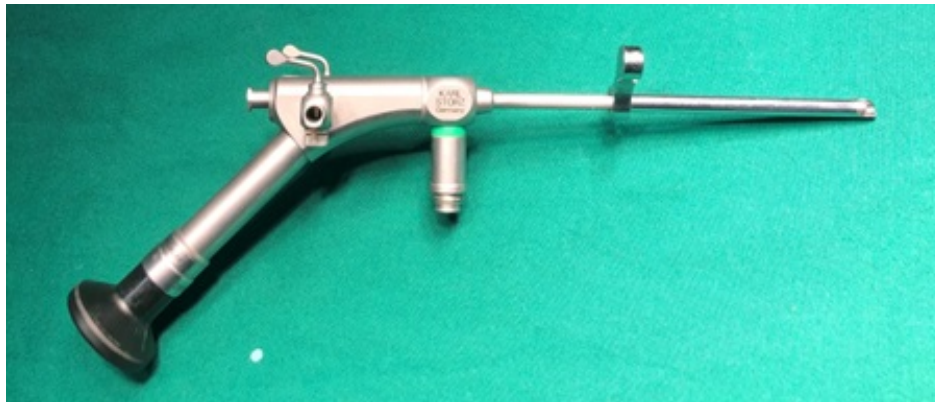

Fig. (3). Photo of a 4-mm Storz cervical endoscope with an inner central working channel measuring 2.7 mm accommodating 2.5 mm instruments. The endoscope has an ocular attachment for commonly available CCD video cameras. The light is attached to the bottom quick connect. The endoscope has two stop-cocks for irrigation fluid and suction channel attachments. The working sleeve has a beveled tip and a vane to help manipulate the working cannular during surgery.

CHAPTER 7

Anterior Transcorporeal Approach of Percutaneous Endoscopic Cervical Discectomy

Zhong-Liang Deng^{1,*}, Lei Chu¹, Liang Chen¹ and Jun-Song Yang²

¹ Department of Orthopaedics, the Second Affiliated Hospital, Chongqing Medical University, Chongqing 400010, China

² Department of Spinal Surgery, Hong-Hui Hospital, Medical College of Xi'an Jiaotong University, Xi'an 710054, China

Abstract: Percutaneous endoscopic cervical discectomy (PECD) was designed to bridge the gap between failed medical- and interventional care for cervical radiculopathy due to small herniated discs and traditional open anterior cervical discectomy surgery many of which employ fusion and far fewer motion preservation strategies. PECD can be divided into the anterior transdiscal- and the posterior interlaminar approach. Anterior PECD has been criticized for the potential propagation of cervical disc collapse due to the more aggressive disruption of the anterior annulus. Additional limitations of the anterior transdiscal PECD may become relevant when upward or downward disc fragments are entrapped behind the vertebral body. Even during ACDF, a corpectomy may be required to remove these far-migrated disc fragments. Therefore, the authors advocated for the anterior transcorporeal approach through a small bony channel through a cervical vertebral body. The surgical trajectory can be freely aimed at the compressed pathology giving the surgeon more flexibility to remove the herniated disc while preserving the motion of the surgical- and possibly adjacent segments by limiting the bony resection required to gain access to the disc herniation. The authors present case examples to illustrate the involved surgical steps, required equipment, discuss pitfalls, and technical details to achieve reliable clinical improvements without complications. This simplified anterior cervical decompression procedure improved their patients without surgery-related complications, such as dysphagia, Horner's syndrome, recurrent laryngeal nerve palsy, vagal nerve injury, tracheoesophageal injury, or anterior cervical hematoma. The authors concluded that the transcorporeal PECD is suitable for the outpatient setting in an ambulatory surgery center, provides excellent direct visualization of the herniated disc with little iatrogenic injury to the cervical spine. Thus, it minimizes the risk of secondary decline of intervertebral height due to access-induced advanced cervical disc degeneration commonly seen with anterior transdiscal approaches.

* Corresponding author **Zhong-Liang Deng:** Department of Orthopaedics, the Second Affiliated Hospital, Chongqing Medical University, Chongqing 400010, China; Tel: 86-13608367586; E-mail: zhongliang.deng@yahoo.com

Kai-Uwe Lewandrowski, Jorge Felipe Ramírez León, Anthony Yeung, Hyeun-Sung Kim, Xifeng Zhang, Gun Choi, Stefan Hellinger and Álvaro Dowling (Eds.)
All rights reserved-© 2021 Bentham Science Publishers

Keywords: Cervical spine, Discectomy, Endoscopy, Herniated disc, Minimally invasive surgery, Transcorporeal approach.

INTRODUCTION

While most spine surgeons accept anterior cervical discectomy and fusion (ACDF) as the gold standard operation for the treatment of symptomatic cervical disc herniations refractory to conservative care [1 - 8], well-recognized problems with the procedure including adjacent segment disease, failure and subsidence of the implants, pseudoarthrosis, and loss of intervertebral height have motivated the development of minimally invasive and simplified alternatives. Some have advocated the percutaneous endoscopic cervical discectomy (PECD) as such an alternative intended to provide treatment to those patients who have failed non-operative medical-, and interventional care. However, who by conventional medical necessity criteria are still not eligible candidates for the ACDF [9 - 12]. PECD permits to approach the cervical spine both from the anterior transdiscal and the posterior interlaminar approach. The anterior approach also carries the risk of injury to the anterior annulus and nucleus pulposus of the cervical intervertebral disc, which has been linked to advanced degeneration of the surgical disc level with the propagation of progressive vertical collapse and in some cases with recurrence of symptoms [13 - 17].

In an attempt to prevent these problems, the anterior endoscopic transcorporeal approach was advocated by George [17, 18]. A myriad of publications employing this transcorporeal approach have been published describing successful clinical outcomes with this anterior cervical decompression and its modified versions, including the microforaminotomy, and the transuncal technique [19 - 28]. Preservation of the cervical disc structure and maintaining the medial wall of the cervical transverse process containing the transverse foramen is the common element to all of these transcorporeal procedures – many of which were with traditional open surgery, or microsurgical technique rather than under direct endoscopic visualization.

In this chapter, the authors present their percutaneous endoscopic version of the anterior transcorporeal approach to a symptomatic cervical disc herniation with illustrative case examples highlighting the clinical advantages of the procedure. The authors will demonstrate how the PECD lends itself to be carried out in an ambulatory surgery center because of shorter operative time and lower surgical risks for intraoperative iatrogenic injury because of the direct magnified endoscopic visualization the painful pathology – the cervical herniated disc.

SURGICAL TECHNIQUE

First, the authors attempted the percutaneous endoscopic anterior cervical discectomy (PECD) in a cadaver study to adopt the endoscopic application technique. The surgery is performed in a supine position with the patient on a radiolucent table and the cervical spine in slight extension and under general anesthesia and continuous electroneurophysiological neuromonitoring. The patient is set up such that intraoperative fluoroscopy images can quickly be taken in the anterior and lateral projection without impeding the surgeon's ability to operate without obstruction by surgical equipment (Fig. 1). The assistant should be on the side of the surgeon. The authors' preferred endoscopic equipment is the cervical set from SPINENDOS GmbH. The surgical level is marked after it has been located on biplanar fluoroscopy views—an 8-mm transverse skin incision, just the sternocleidomastoid muscle, and slightly below the surgical level. The content of the tracheoesophageal groove is pushed medial and the carotid sheath lateral employing the two-finger technique. This technique allows the creation of a small safe window to advance a spinal needle to target the surgical cervical vertebral body in a trajectory best suited for accessing the surgical pathology. A right-handed surgeon should push the entire tracheoesophageal content is pushed to the opposite side with the left-hand index- and middle finger.

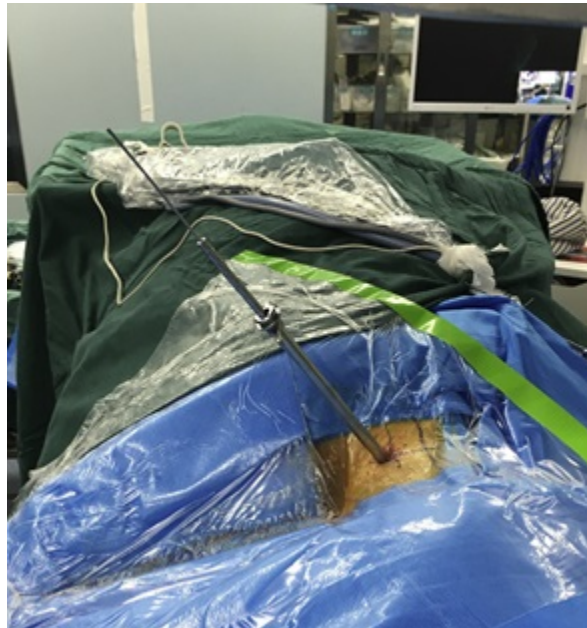

Fig. (1). Along with the guidewire, the dilator sheath and the outer working sheath were inserted sequentially via the created intracorporeal hole into the targeted vertebral body.

CHAPTER 8

Anterior Endoscopic Cervical Discectomy and Foraminoplasty for Herniated Disc and Lateral Canal Stenosis

Jorge Felipe Ramírez León^{1,2,*}, José Gabriel Rugeles Ortiz¹, Carolina Ramírez Martínez¹, Nicolás Prada Ramírez^{1,3}, Enrique Osorio Fonseca⁴ and Gabriel Oswaldo Alonso Cuéllar¹

¹ Minimally Invasive Spine Center for Latinamerican Endoscopic Spine Surgeons, LESS Invasiva Academy, Bogotá, D.C., Colombia

² Fundación Universitaria Sanitas, Bogotá, D.C., Colombia

³ Colombia Clínica Foscal, Bucaramanga, Colombia

⁴ Universidad El Bosque, Bogotá, D.C., Colombia

Abstract: Cervical foraminotomy is a popular procedure with surgeons to treat patients with refractory cervical radicular pain. Traditionally, it has been performed from the posterior approach. With the advent of minimally invasive spinal surgery techniques (MISST), anterior methods have also been employed to approach the compressive pathology from the axilla of the painful cervical nerve root. The authors of this chapter present their technique of transdiscal endoscopic anterior cervical discectomy foraminoplasty using an instrument system comprised of serial dilators, trephines, rongeurs, and a pulsed radiofrequency probe. They demonstrate the steps of the procedure from patient positioning, placement of surgical access, the employment of the individual surgical instruments, and their clinical outcomes. The authors briefly describe their clinical experience over a twenty-one year period. They performed a total of 232 procedures on 169 patients with single and up to 4 level surgeries herniate disc (219/232; 94.39%). An additional 13 patients (4.9%) had procedures for the treatment of lateral cervical canal stenosis. At a one-year follow-up, 90% of patients were rated to have had Excellent and Good Macnab outcomes, whereas Fair and Poor results were reported by 7%, and 3% of patients, respectively. In the absence of intraoperative or postoperative complications or reoperations associated with the procedure, the authors recommended it as a simplified outpatient alternative to anterior cervical discectomy and fusion.

* Corresponding author Jorge Felipe Ramírez León: Minimally Invasive Spine Center for Latinamerican Endoscopic Spine Surgeons, LESS Invasiva Academy, Bogotá, D.C., Colombia; Tel: +57 1 6002555; E-mail: academy@lessinvasiva.com

Kai-Uwe Lewandrowski, Jorge Felipe Ramírez León, Anthony Yeung, Hyeun-Sung Kim, Xifeng Zhang, Gun Choi, Stefan Hellinger and Álvaro Dowling (Eds.)

All rights reserved-© 2021 Bentham Science Publishers

Keywords: Anterior approach, Cervical disc herniations, Endoscopic surgery, Foraminal stenosis, Outpatient, Pulsed radiofrequency, Radicular pain.

INTRODUCTION

Robinson and Smith in 1955 first reported the anterior cervical discectomy and fusion (ACDF) technique [1]. ACDF has become the principal surgery for cervical herniated disc and stenosis in the anterior central and lateral canal stenosis. Although clinical outcomes with ACDF are generally good with the procedure being considered one of the better spinal surgeries with high patient satisfaction, concerns of developing adjacent segment disease (ASD) and the need for another fusion surgery remains [2 - 8]. Many strategies to avoid ASD following ACDF with open surgery have been entertained. Several minimally invasive spinal surgery technologies (MISST) have received attention due to significant technological advances in both endoscopic equipment and implants [2, 3, 6]. However, the burden of proof of the superiority of one MISST over another in treating cervical herniated disc and stenosis still rests with their advocates.

BACKGROUND

Cervical lateral stenosis refers to the narrowing of the neuroforamen for the exiting nerve roots at each respective level. This pathology can be caused by a herniated disc, presence of osteophytes. The latter are often induced by degeneration or microfractures of adjacent bony structures, or occur in combination herniated disc. Periosteal distention due to bulging disc has also been recognized as a stimulus to the formation of osteophytic bone spurs, which can encroach on the cervical neural elements. In its early stages, cervical stenosis may be asymptomatic [9], but when radiculopathy develops, the predominant symptom is axial neck pain radiating to the arm in its corresponding dermatome. Radiating pain and its dermatomal distribution correspond to the affected level. Concomitant cervical myelopathy is uncommon but can be observed in some cases. The diagnosis is based on a detailed history and physical examination (H&P). The onset and type of pain and corresponding diagnostic information, including radiography (A-P, lateral, extension & flexion views) MRI and CT scans. Although the course of cervical radiculopathy is generally favorable, approximately 25% of patients with degenerative processes of the cervical spine may require surgery once persistent symptoms are non-responsive to conservative care such as the use of analgesics, physiotherapy, soft collar, epidural steroid injections, and selective nerve blocks [10]. Therefore, non-operative therapeutic measures should be tried first. Surgery is generally considered when non-operative measures for the patient's intense, unrelenting pain or progressive neurological deficit have failed. Typically, a minimum of 6 weeks of non-

operative treatment is thought to be appropriate before considering surgery [11, 12]. The choice of surgical procedure depends on individual surgeon training and preference and the availability of necessary surgical instruments and implants.

OBJECTIVE

Surgical options for cervical decompression can generally be divided into three groups: open, mini-open, and endoscopic procedures. The open or conventional technique was developed in 1950 and is now widely accepted as gold standard surgical treatment for cervical foraminal stenosis [13 - 15]. Open surgical treatment options include open foraminotomy or anterior cervical discectomy and fusion (ACDF) combined with decompression and/or fusion procedure. With the intent of minimizing morbidity associated with conventional open procedures, minimally invasive techniques have been recently developed for lateral stenosis. These included mini-open and endoscopic techniques. Both mini-open and endoscopic cervical decompression techniques have recently gained more popularity because of decreased approach related problems, including blood loss, postoperative pain, and muscle atrophy [16, 17]. In this chapter, the authors will discuss their results and compare them to those of endoscopic cervical foraminoplasty procedure. The authors have used endoscopic methods for the treatment of cervical radicular pain for the last 19 years.

ANTERIOR ENDOSCOPIC CERVICAL FORAMINOPLASTY

Anterior Endoscopic Cervical Foraminoplasty (AECF) is the removal of degenerated tissue compressing nerve structures in the foraminal area under an endoscope view from an anterior percutaneous approach. The surgical principle is the same as in open decompression and aims to expand the foraminal window, remove the hypertrophic tissue and osteophytes to achieve decompression of neural structures. One of its advantages is that it can be performed on one or several levels without a fusion need.

Indications

We have initial indications for the anterior cervical endoscopic approach: contained or extruded non migrated discal hernias or hernias with lateral fragments [18, 19] and stenosis foraminal produced by osteophytes [18, 20]. Recently some authors described the feasibility of the use of an anterior endoscopic approach for ossified posterior longitudinal ligament (OPLL) and cervical spondylotic myelopathy (CSM) using anterior full-endoscopic percutaneous trans corporeal procedure, the approach has been successfully used in a case report of OPLL and in a study with 2 years follow-up for single segment CSM [21, 22].

CHAPTER 9

Posterior Full Endoscopic Cervical Discectomy & Foraminotomy

Álvaro Dowling^{1,2}, Kai-Uwe Lewandrowski^{3,4,5,*} and Hyeun Sung Kim^{6,7,8,9,10}

¹ Endoscopic Spine Clinic, Santiago, Chile

² Department of Orthopaedic Surgery, USP, Ribeirão Preto, Brazil

³ Center for Advanced Spine Care of Southern Arizona and Surgical Institute of Tucson, Tucson, AZ, USA

⁴ Department of Orthopaedic Surgery, UNIRIO, Rio de Janeiro, Brazil

⁵ Department of Orthopaedic Surgery, Fundación Universitaria Sanitas, Bogotá, D.C., Colombia, USA

⁶ Department of Neurosurgery, Nanoori Gangnam Hospital, Seoul, Republic of Korea

⁷ A President of the Korean Research Society of the Endoscopic Spine Surgery (KOESS), South Korea

⁸ A Faculty of the Korean Minimally Invasive Spine Surgery Society (KOMISS), South Korea

⁹ A Chairman of the Nanoori Hospital Group Scientific Team, South Korea

¹⁰ An Adjunct Professor of the Medical College of the Chosun University, Gwangju, South Korea

Abstract: Cervical radiculopathy is a common disabling condition resulting from advanced degeneration of the cervical spine. Posterior Endoscopic Cervical Discectomy (PECD) surgery preserves soft tissue and accomplishes a form of foraminal decompression with a lower propensity to postoperative instability. The authors described the technique in detail with an illustrative case example and intraoperative endoscopic images. The targeting point is the “V” point made up by the lateral margin of interlaminar space and medial border of facet joint junction. This confluence of the medial junction of the superior and inferior facet can easily be recognized on AP view where it has the appearance of a V. Furthermore; the authors present the results of a prospective clinical PECD study of 29 levels in 25 patients where they analyzed the radiological and clinical outcome with the trans v point PECD technique. Most of the PECD surgeries were carried out at the C5/6 and C6/7 levels. The mean follow up was 29.6 months. There was a 4% complication rate because of motor deficits, which had been resolved after one year. The majority of patients

* **Corresponding author Kai-Uwe Lewandrowski:** Center for Advanced Spine Care of Southern Arizona and Surgical Institute of Tucson, Tucson, AZ, USA, Department of Orthopaedic Surgery, UNIRIO, Rio de Janeiro, Brazil and Department of Orthopaedic Surgery, Fundación Universitaria Sanitas, Bogotá, D.C., Colombia, USA; Tel: +1 520 204-1495; Fax: +1 623 218-1215; E-mail: business@tucsonspine.com

Kai-Uwe Lewandrowski, Jorge Felipe Ramírez León, Anthony Yeung, Hyeun-Sung Kim, Xifeng Zhang, Gun Choi, Stefan Hellinger and Álvaro Dowling (Eds.)
All rights reserved-© 2021 Bentham Science Publishers

showed significant improvements in VAS and ODI scores, and 96% achieved good and excellent results by Macnab's criteria. Retrospective evaluation of the radiological and CT data showed sagittal foraminal area increase and craniocaudal foraminal length increases. PECD produced the largest foraminal length increase preferentially in the ventrodorsal direction. Based on our observations, PECD is a good option in the posterior foraminotomy of the cervical spine. Clinical and radiological outcomes are favorable.

Keywords: Cervical radiculopathy, Full endoscopic discectomy, Posterior cervical foraminotomy.

INTRODUCTION

Spurling and Scoville introduced posterior cervical foraminotomy (PCF) first in the mid-20th century [1]. Conventional posterior foraminotomy is traditionally performed through an open approach with a midline incision for bilateral decompression or paraspinal incisions for unilateral decompression. In 2001, micro-endoscopic laminoforaminotomy reports appeared introducing minimally invasive spinal surgery techniques to avoid more extended hospital stays, general anesthesia (GA), more significant operative blood loss, longer recovery and rehabilitation times, increased soft tissue damage, higher risk of operative complications, and minimizing pain associated with the procedure [2 - 4]. Percutaneous, minimally invasive, and endoscopic approaches are attractive alternatives to open surgery [5].

Nowadays, the posterior full-endoscopic cervical discectomy (PECD) with or without foraminotomy is a well-established procedure, with many authors having reported favorable clinical outcomes [6, 7]. This chapter's authors still thought that it is worth reviewing the most contemporary techniques by giving some illustrative examples of their clinical practice to complete this exhaustive text on cervical spinal endoscopy. For the novice endoscopic spine surgeon, PECD is likely the most facile endoscopic surgery technique of the cervical spine to learn and less risky than anterior cervical full-endoscopic surgery. It is a useful technique in any endoscopic spine surgeon's hands, for which reason the authors presented their contemporary version of PECD in this chapter.

CLINICAL PRESENTATION

Cervical radiculopathy with unrelenting radiating upper extremity, shoulder, upper back or neck shoulder and arm pain radiating into the hand is the hallmark symptom caused by a stenotic process in the cervical neuroforamen [8]. Shoulder-related pathology from rotator cuff tears or other internal shoulder derangements, including a detachment of the long head of the biceps anchor attachment from the

glenoid, should be excluded [9]. Another important differential diagnosis to consider is double-crush peripheral nerve compression syndromes in the upper extremities and cause similar symptoms [9]. The patients' pain from cervical radiculopathy is typically described as sharp, tingling, dull, aching, or burning. Decreased sensation or dysesthesias often precede the classic radiculopathy pain [9]. Provocative testing, such as the incitement of the Spurling sign, may aid in the diagnosis [10]. Patients complain of more pain when turning the head toward the painful side or by reporting pain relief by elevating the arm above the shoulder and placing it onto the head – a shoulder-abduction relief sign which is thought to be more representative of a soft herniation. Some authors suggested a negative shoulder-abduction relief sign in a patient with a positive Spurling sign may indicate the cervical neuroforamen's bony encroachment. Typically, patients presenting to the endoscopic spine surgeon with these complaints have already undergone conservative management with non-steroidal anti-inflammatories (NSAIDs) and physical therapy (PT). However, the authors recommend that each patient undergo a minimum of 6 weeks of conservative treatment, additionally including analgesics, activity modification, short-term cervical bracing, facet blocks, and in select cases, cervical transforaminal epidural steroid injections before considering them for surgery. Auxiliary electrodiagnostic studies such as electromyography (EMG) and nerve conduction studies (NCS) may aid in diagnosing [11]. Detailed history taking, physical examination, and clinical judgment are critical in determining the predominant pain generator's location in the cervical spine, as is a careful evaluation of advanced imaging studies, including magnetic resonance imaging (MRI) or the computed tomography (CT) scans [12].

ADVANTAGES OF ENDOSCOPICALLY VISUALIZED POSTERIOR FORAMINOTOMY

There are some obvious and perhaps not so obvious advantages of using the endoscopic surgery technique. Since the endoscopic working cannula is inserted after the introduction of progressive dilation tubes it can be freely maneuvered or held by an assistant while the surgeon freely inserts the endoscope with his/her non-dominant hand and controls the suction and endoscopic instruments with their dominant hand. Typically, nothing is fixed to any equipment or mounting arm and the endoscope is freely maneuvered inside the working cannula. It is the authors' experience that this operative technique allows for:

1. Exclusive visual angles,
2. Better illumination of deep structures, and
3. Verification of the nerve root trajectory.

CHAPTER 10

Posterior Endoscopic Decompression for Cervical Spondylotic Myelopathy

Yuan Heng¹, Zhang Xi-feng², Zhang Lei-ming³, Yan Yu-qiu⁴, Liu Yan-kang^{1,5}
and Kai-Uwe Lewandrowski^{5,6,7,*}

¹ Shanxi Medical University, Taiyuan 030001, China

² Department of Orthopedics, First Medical Center, PLA General Hospital, Beijing 100853, China

³ Department of Neurosurgery, the Sixth Medical Center, PLA General Hospital, Beijing 100048, China

⁴ Minimally Invasive Spinal Surgery, Beijing Yuhe Integrated Traditional Chinese and Western Medicine Rehabilitation Hospital, Beijing 100039, China

⁵ Center for Advanced Spine Care of Southern Arizona and Surgical Institute of Tucson, Tucson, AZ, USA

⁶ Department of Orthopaedic Surgery, UNIRIO, Rio de Janeiro, Brazil

⁷ Department of Orthopaedic Surgery, Fundación Universitaria Sanitas, Bogotá, D.C., Colombia, USA

Abstract: The authors describe the technique and clinical outcomes with the posterior endoscopic cervical spinal cord compression to treat cervical spondylotic myelopathy. A total of twenty-two cervical spondylotic myelopathy patients were treated with endoscopic spine surgery fusion from January 2015 to June 2017 at the Medical School of Chinese PLA. The operation time, intraoperative blood loss, and hospitalization stay were recorded and compared. Japanese Orthopaedic Association (JOA) scores before the operation, three months, and one year after operation were recorded and analyzed. There were twenty-two cases in the spinal endoscopy group. There were significant differences in preoperative JOA scores three months after surgery and one year after surgery. The JOA scores were significantly increased after surgery, and the symptoms gradually improved postoperatively. Clinical outcomes were Excellent in 81.8% of patients. The efficacy and safety of endoscopic spinal surgery for single-level cervical spondylotic myelopathy were established. The operation time, the intraoperative blood loss, and the hospitalization stay were reduced compared to historical numbers for competing decompression and fusion procedures.

* **Corresponding author Kai-Uwe Lewandrowski:** Center for Advanced Spine Care of Southern Arizona and Surgical Institute of Tucson, Tucson, AZ, USA, Department of Orthopaedic Surgery, UNIRIO, Rio de Janeiro, Brazil and Department of Orthopaedic Surgery, Fundación Universitaria Sanitas, Bogotá, D.C., Colombia, USA; Tel: +1 520 204-1495; Fax: +1 623 218-1215; E-mail: business@tucsonspine.com

Kai-Uwe Lewandrowski, Jorge Felipe Ramírez León, Anthony Yeung, Hyeun-Sung Kim, Xifeng Zhang, Gun Choi, Stefan Hellinger and Álvaro Dowling (Eds.)
All rights reserved-© 2021 Bentham Science Publishers

Keywords: Cervical spondylotic myelopathy, Decompression, Gait imbalance, Laminectomy, Motion preservation, Non-fusion, Posterior cervical approach, Spinal cord compression, Spinal endoscopy, Upper motor neuron dysfunction.

INTRODUCTION

Cervical spondylotic myelopathy (CSM) is spinal cord dysfunction caused by spinal cord degeneration. Compressive pathology may cause reduced blood supply and further contribute to the deterioration of the cervical myelon [1 - 3]. CSM has a high incidence among middle-aged and older adults over age 55 [4]. Patients with mild clinical symptoms may be successfully treated with physical therapy, massage, intermittent soft cervical collar bracing. Non-steroidal anti-inflammatory drugs also play a minor role [5, 6]. For patients with severe clinical signs of progressive deterioration of neurological function, surgery is recommended [7].

Anterior cervical decompression and fusion (ACDF) [8 - 13] and posterior cervical decompressions *via* laminectomy-, or laminoplasty technique with or without fusion remains the mainstream of surgical CSM treatment. The efficacy and safety of these [14 - 17] types of procedures have been established in short-[1, 2], and long- [18 - 23] term studies, mainly when applied in patients with multilevel disease. However, these surgeries are associated with significant morbidity due to soft tissue trauma from open incisions, muscle atrophy from prolonged retraction, increased blood loss, and implant-related problems. These disadvantages are of particular relevance to posterior decompressive procedures. The anterior approach exploiting the access to the anterior cervical spine afforded by blunt dissection of the tracheoesophageal groove carries the risk of dysphagia [24], recurrent laryngeal nerve palsy, Horner syndrome, vagal nerve injury, tracheoesophageal- and vascular damage, postoperative hematoma [25], intervertebral disc infection, or postoperative headaches [10, 26 - 33]. In addition, ACDF is associated with adjacent segment disease (ASD) [34, 35].

Endoscopic surgery may be an alternative to open decompression, particularly if the compressive pathology extends only over one or two levels. A few authors have demonstrated the feasibility, indications, complications, and clinical efficacy of endoscopic spinal surgery for this disease [36 - 39]. In this chapter, the authors describe the technical steps of a one- or two-level posterior endoscopic decompression in 22 patients who underwent surgical treatment and complete follow-up in the General Hospital of the People's Liberation Army for the past three years for symptomatic CSM.

CLINICAL SERIES

There were 22 patients treated with spinal endoscopy, 14 males (63.6%), eight females (36.4%) with an average age of 42.41 ± 7.06 years. Among them, 16 patients had single-level compressive lesions, and six patients had two-level compressive lesions. Two patients had a history of trauma, 14 patients suffered from upper limb motor dysfunction, 15 patients displayed lower limb motor dysfunction, and another nine patients suffered from combined upper and lower limb dysfunction. The preoperative workup included routine plain film x-ray, CT, and MRI studies of the cervical spine. The compressive pathology was often constituted by different degrees of disc herniation (15 patients), posterior marginal hypertrophy (2 patients), and ligamentum flavum hypertrophy (2 cases). Three patients had and spinal cord degeneration with evidence of myelomalacia on preoperative MRI scanning. Patients were enrolled in this consecutive cohort study if they had preserved motor function in the limbs, decreased or lost sensory function, positive pathological upper motor neuron signs, a preoperative JOA score \leq of 12 points, neck and shoulder pain, and upper limb pain VAS > 6 points. Only patients with advanced imaging studies showed corroborating compressive pathology, including cervical degenerative disease, spinal stenosis, and spinal cord compression, consistent with the correlative clinical symptoms and signs. Moreover, the authors limited patient selection for the endoscopic spinal cord decompression with single- or two-level cervical spinal stenosis. Patients with bony cervical spinal stenosis, severe vertebral posterior marginal osteophyte formation, posterior longitudinal ligament ossification, congenital developmental cervical spinal stenosis, large cervical disc herniation, cervical intervertebral disc prolapse, and apparent cervical segmental instability and significant focal kyphosis were excluded.

ENDOSCOPIC SURGICAL TECHNIQUE

Surgeries were performed under local anesthesia with the patient in a prone position with the neck flexed and fixed in tongues. Placing the head in capital flexion and cervical extension should facilitate access to the posterior elements. The surgical level and skin entry point were identified with the fluoroscopy unit placed in the anterior-posterior plane. The skin is prepped in standard surgical fashion, and a layer-by-layer infiltration with local anesthesia is applied. An 18G spinal needle was advanced to the trailing edge of the lamina of the surgical level. The trajectory of the guidewire is checked in both fluoroscopic planes. A skin incision is made around the guidewire, and serial dilators are advanced over it. The endoscopic working cannular is then placed at the surgical cervical lamina medical trailing edge to the facet joint complex. Typically, around a 7-mm working cannula was used to introduce the endoscope and directly visualize the

CHAPTER 11

Full Endoscopic Partial Pediculotomy, Partial Vertebrotomy Technique For Cervical Degenerative Spinal Disease

Pang Hung Wu^{1,6}, Hyeun Sung Kim^{1,2,3,4,5,*} and Il-Tae Jang¹

¹ Department of Neurosurgery, Nanoori Gangnam Hospital, Seoul, Republic of Korea

² A President of the Korean Research Society of the Endoscopic Spine Surgery (KOSESS), South Korea

³ A Faculty of the Korean Minimally Invasive Spine Surgery Society (KOMISS), South Korea

⁴ A Chairman of the Nanoori Hospital Group Scientific Team, South Korea

⁵ An Adjunct Professor of the Medical College of the Chosun University, Gwangju, South Korea

⁶ Departments of Orthopaedic Surgery, National University Health System, Jurong Health Campus, Singapore

Abstract: The challenges of decompression surgeries performed in the cervical spine for degenerative spinal disease are 1) the avoidance of injuries to vital structures, 2) prevention of neurological deterioration, or deficit 3) preservation of cervical segmental stability to avoid post-decompression kyphosis 4) adequate decompression of neural structures. Endoscopic spine surgery optimizes two essential aspects of minimally invasive spine surgery: optimal visualization and minimal soft tissue damage. Despite using a small diameter endoscope, the proximity of exiting nerve root, spinal cord, and pedicle to the intervertebral disc make posterior endoscopic cervical foraminotomy and discectomy difficult. To remove the disc without significant neural retraction, our technique of full endoscopic partial pediculotomy, partial vertebrotomy posterior endoscopic cervical foraminotomy and discectomy (PECFD) allows the creation of a subneural working space for the endoscopic equipment to reach the prolapsed disc or hypertrophic uncovertebral joint. This chapter describes this technique and its clinical pearls to perform PPPV PECFD safely and efficiently.

Keywords: Cervical radiculopathy, Degeneration, Full endoscopic partial pediculotomy, Partial vertebrotomy technique.

* **Corresponding author Hyeun Sung Kim:** Department of Neurosurgery, Nanoori Gangnam Hospital, Seoul, Republic of Korea, A President of the Korean Research Society of the Endoscopic Spine Surgery (KOSESS), South Korea, A Faculty of the Korean Minimally Invasive Spine Surgery Society (KOMISS), South Korea and A Chairman of the Nanoori Hospital Group Scientific Team, South Korea; E-mail: neurospinekim@gmail.com

Kai-Uwe Lewandrowski, Jorge Felipe Ramírez León, Anthony Yeung, Hyeun-Sung Kim, Xifeng Zhang, Gun Choi, Stefan Hellinger and Alvaro Dowling (Eds.)
All rights reserved-© 2021 Bentham Science Publishers

INTRODUCTION

The incidence of cervical degenerative spinal disease increases with age. Most adults aged above 40 years have severe cervical degeneration in one or more of the levels in MRI based population studies [1]. Fortunately, most of the patients are usually asymptomatic. Cervical degenerative spinal disease typically presents as degenerative disc disease and facet arthropathy with axial neck pain. As the degeneration progresses, the compression of the uncovertebral joint, bulging or prolapsing intervertebral disc, facet hypertrophy, and buckling of ligamentum flavum and posterior longitudinal ligament on the exiting nerve root can lead to cervical radiculopathy. The cervical spinal cord's compression can lead to myelopathy [2]. Conservative management includes physiotherapy, spinal injection, and immobilization by cervical collars. Cervical traction is helpful in most of the patients with cervical radiculopathy patients [3]. There is no clear consensus of surgical indications with cervical radiculopathy. Often a protracted failure of conservative management with progressive neurologic deficits and signs of evolving myelopathy indicates operative management [4]. Anterior cervical and posterior cervical approaches for radiculopathy have both achieved good clinical results at an average of 12-43 months after surgery [5]. Posterior cervical foraminotomy has a low risk of index level fusion rate and adjacent segment disease requiring around 1%, respectively [6]. However, posterior cervical foraminotomy significantly decreased the risk of recurrent laryngeal nerve palsy, dysphagia, trachea-esophageal injuries, and preserved cervical motion. The disadvantage in traditional open posterior cervical foraminotomy is extensive soft tissue dissection to expose the laminofacet junction of the index level (V point) [7]. Since endoscopic spine surgery started its development in the lumbar spine, technical and technological improvement has extended its indications to most of the lumbar degenerative conditions and more recently to cervical spine neurodegenerative diseases as well [8].

The full endoscopic cervical approach can be divided into an anterior and posterior procedure. Anterior Endoscopic Cervical Discectomy is an effective method with excellent clinical outcomes [9]. However, there is an inherent danger of significant organ injuries such as a carotid artery, esophagus, and trachea injuries with these vital structures close to the docking point. Posterior endoscopic cervical foraminotomy and discectomy have the benefits of directly docking onto the V point by serial dilation to minimize soft tissue damage. It is possible to treat a large percentage of degenerative cervical diseases [10]. Improved vision by optical lens magnification at the endoscope's distal tip with direct delivery of instruments through the working channel of endoscope under endoscopic vision improves safety in decompression posterior cervical bony and soft tissue [11]. Cervical exiting nerve root and cervical spinal cord injuries are dreaded

complications of posterior approaches. There are advantages in minimizing the neural elements retraction in posterior endoscopic cervical foraminotomy and discectomy (PECFD).

In this chapter, we elaborate on the technique of full endoscopic partial pediculotomy, partial vertebrotomy posterior endoscopic cervical foraminotomy and discectomy (PPPV PECFD) which is done to create sufficient space to occupy a small endoscopic working cannula and decreases the amount of retraction of neural elements necessary to remove the prolapsed disc and decompress the uncovertebral joint of the index level.

RATIONALE

Anatomical Relationship of Cervical Disc, Pedicle & Exiting Nerve Root

The exiting cervical nerve root exits the spinal canal above their number vertebra, *i.e.*, C5 nerve root passes above the C5 pedicle and passes through the C4/5 intervertebral foramen. The exiting cervical nerve root commonly arises from its corresponding spinal cord and traverses just above their numbered pedicle. The cervical disc's lateral margin is closely associated with the superior and medial aspect of the pedicle (Fig. 1).

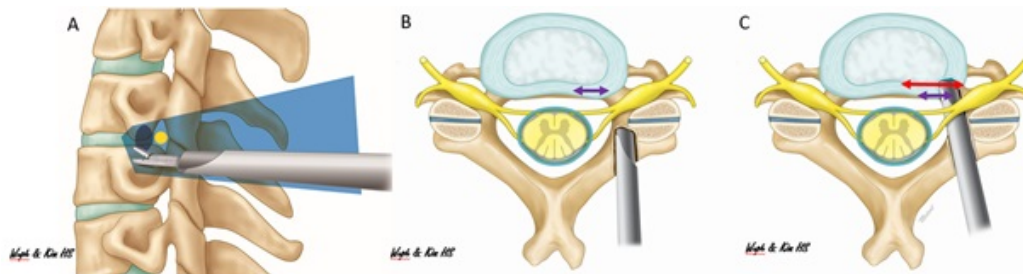


Fig. (1). Illustrative drawing of Partial Pediculotomy Partial Vertebrotomy Posterior endoscopic cervical foraminotomy and discectomy (PPPV PECFD). **(1a):** Sagittal View and the amount of decompression in blue shadow. **(1b):** Purple double arrow showed the amount of disc exposure in traditional PECFD. **(1c):** Red double arrow showed the amount of disc exposure in PPPV PECFD.

Current Limitation of Posterior Endoscopic Cervical Foraminotomy and Discectomy

The intimate relationship of the cervical nerve roots with the bony confines of the cervical spinal canal coupled with low tolerance of retraction for cervical neural elements poses significant challenges to retrieving prolapsed cervical disc and the uncovertebral joint decompression. The incidence of neurological complications of posterior cervical surgeries was reported to be around 0.18%, [12] while C5 palsy around 3.4% [13]. The occurrence of these neurological complications is

CHAPTER 12

Full Endoscopic Anterior Cervical Decompression & Fusion With Iliac Crest Dowel Graft

Stefan Hellinger^{1,*}

¹ Department of Orthopedic and Spine Surgery, Arabellaklinik, Munich, Germany

Abstract: Isolated discogenic cervical pain syndromes are somewhat difficult to treat. Many of these patients have underlying painful degenerative conditions of the cervical spine that do not meet accepted criteria for surgical treatments. Hence, many of these patients remain untreated or undergo interventional pain management procedures to meliorate the pain. The author presents a simple endoscopic outpatient method intended to treat a small subsection of this patient population complaining of isolated neck pain without any arm pain. Often these patients have end-stage degenerative cervical disc disease with near complete collapse with minimal associated foraminal stenosis. The author presents an endoscopic interbody fusion technique he has developed for these types for patients using an autograft bone dowel harvested from the iliac crest.

Keywords: Autograft, Cervical spine, Degenerative disc disease, Discogenic pain, Dowel graft, Endoscopic, Iliac crest graft, Minimally invasive, Outpatient surgery, Percutaneous.

INTRODUCTION

The incidence of cervical discogenic pain symptoms in the general population is high [1 - 7]. In Germany, insurance claims analysis estimated that one in five patients visit their orthopedic surgeon for symptomatic cervical disc syndromes [8]. The treatment of cervical discogenic diseases makes high is challenging both in terms of diagnostic work-up and treatment [9]. Advances in medical imaging and neurological testing have enhanced the diagnostic accuracy in identifying those patients with isolated discogenic neck pain without cervical radiculopathy [10 - 15]. Typically, patients with isolated discogenic neck pain without neurological symptoms are initially denied effective surgical treatments since the

* Corresponding author Stefan Hellinger: Department of Orthopedic and Spine Surgery, Arabellaklinik, Munich, Germany; E-mail: hellinger@gmx.de

literature on beneficial therapies is not as favorable as for cervical disc herniations causing radiculopathy or spinal cord dysfunction [6].

The most common cause of cervical pain syndromes is a degenerative change in the intervertebral disc. The disease may be accompanied by painful displacement of disc tissue causing mechanical compression, inflammation, and vascular compromise of neural structures [1, 16, 17]. A myriad of well-understood symptoms may arise: a) pain in the neck and head region, b) radiating into the arms, and hands, and at its worst cervical myelopathy [16]. More subtle causes of neck pain stemming from the cervical intervertebral disc may relate to tears in the dorsal annulus fibrosus. Additional sources of cervical pain may arise from the vertebral bodies, the periosteum, joint- and ligament complexes both in the anterior and posterior columns [1]. Thankfully, over 80 percent of patients with these symptoms experience spontaneous resolution with supportive medical and interventional care measures including physical therapy, non-steroidal anti-inflammatories, spinal injections, acupuncture, massage- or chiropractic care, and activity modification [18, 19].

In this chapter, the author attempted to highlight a full endoscopic technique of performing an anterior cervical decompression fusion with an iliac crest bone dowel intended to treat those patients with failed conservative therapies and a conclusive diagnostic work-up for isolated cervical discogenic pain. The concept of using the full-endoscopic technique is based both on reducing the burden associated with more traditional cervical disc surgery, and by offering a more simplified method of treating the condition in an ambulatory surgery setting to reduce operation related morbidity, and cost.

HISTORICAL CONSIDERATIONS

The development of surgical procedures for intervertebral disc treatment began in 1908 with the transdural removal of disc tissue with the aid of laminectomy by Oppenheimer and Krause. Extradural extirpation of a herniated disc proposed by Mixter and Barr in 1934 [20]. Stookey began looking at cervical intervertebral disc displacements [21]. The intervention was developed on the lumbar spine, progressing from laminectomy to hemilaminectomy, and then to fenestrotomy and finally endoscopy (Hijikata 1989) [22]. The first operation on the cervical spine was performed by Elsberg in 1922, also transdurally [23]. As of 1958, anterior approaches were introduced by Cloward [24], Smith, and Robinson [25], and these are still standard procedures in the surgical treatment of cervical pathologies. Ultimately, these decompression techniques have been combined with the fusion of the segment by a bone graft.

While time-proven, anterior cervical discectomy and fusion (ACDF) continues to be plagued by the problems of access morbidity such as injury to the recurrent laryngeal nerve (RLN) or swallowing problems [26]. Apfelbaum reported RLN lesions between 11%-15% [27]. The desire to reduce access-related morbidity prompted the application of alternative treatments such as the posterior cervical foraminotomy. In revisiting the past, surgeons with a preference for the anterior approach ask whether cervical interbody fusion is necessary? Cervical artificial disc replacement has been offered as an alternative with the intent of reducing reoperation rates for adjacent segment disease by preserving motion [28 - 33]. However, this procedure suffers from similar access related problems. Dating back to 1960, Hirsch *et al.* reported his results with anterior cervical discectomy without fusion or an implant [34]. Cervical chemonucleolysis was introduced by Smith in 1964 [35]. Similarly, automated discectomy (Onik 1985) [36], percutaneous laser disc decompression, and nucleotomy [37] and the use of radiofrequency (Coblation 2003) [38] added to the spectrum of percutaneous cervical surgeries. Many studies reported clinical outcomes comparable to fusion [39]. Additional studies corroborated these results by offering limited disc removal in favor of a more targeted and selective procedure [40, 41].

THE OBJECTIVE

The aim is to miniaturize the anterior cervical surgery further. Non-endoscopic percutaneous procedures were previously used in select patients with excellent results and a complication rate of less than 1 percent (Hellinger 2004) [42, 43]. Incorporation of endoscopy into the percutaneous techniques was for the author a natural progression of his development strategies for simplified, less burdensome ambulatory anterior cervical surgeries. Pioneers of the endoscopy of the cervical spine were Lee [44 - 46], Chiu [37, 47], and Fontanella [48]. These authors reported their outcomes with their minimal access anterior cervical surgery in the early 1990ies, which hinged about leaving a large proportion of the intervertebral disc, in particular, most of the annulus fibrosus preserved. Removing only the painful pathology selectively in the area of the nucleus pulposus and on the dorsal fibrous ring where symptomatic neural element compression occurred was recommended by these authors and others [49, 50]. They stipulated that the remaining disc tissue preserved some biomechanical function of the degenerated intervertebral disc. Adding the video-endoscopy to these techniques was an easy-to-implement modification not only because of improved visualization but also because of the ability to ablate and shrink diseased tissue with the use of a laser [51]. Consequently, the risk of complications was further reduced while enhancing the efficiency of the treatment, thereby making it suitable for an ambulatory surgery setting. Additional advancements of the endoscopic technique

CHAPTER 13

Percutaneous Endoscopically Assisted Cervical Facet Reduction

Xifeng Zhang¹, Zhu Zexing¹ and Jiang Hongzhen^{2,*}

¹ Department of Orthopedics, First Medical Center, PLA General Hospital, Beijing 100853, China

² Minimally Invasive Spinal Surgery, Beijing Yuhe Integrated Traditional Chinese and Western Medicine Rehabilitation Hospital, Beijing 100853, China

Abstract: The authors describe the percutaneous endoscopic release of jumped and locked cervical facet joints under direct visualization as an alternative technique to open posterior decompression and reduction under capital traction. Instead of under general anesthesia, the procedure can be done under local anesthesia allowing the surgeon to communicate verbally with the injured patient while directly visualizing the decompression, release, and spontaneous reduction of the locked facet, thus, lowering the risk of unrecognized grave neurological complications. The author's endoscopic technique affords the surgeon the ability to provide the patient with a more simplified solution to the jumped and locked facet problem, thereby decreasing the overall morbidity and surgical risks associated with a combined anterior and posterior approach typically performed for this condition. The authors present a representative case example to illustrate their technique.

Keywords: Cervical facet dislocation, Decompression, Jumped facets, Laminectomy, Locked facets, Posterior cervical approach, Spinal cord compression, Spinal endoscopy, Upper motor neuron dysfunction.

INTRODUCTION

Dislocations of the cervical spine are the result of flexion-rotation injuries [1]. [2] Typically, they occur between the C3 and T1 level. As a consequence of this injury, the superior facet dislocates forward in relationship to the inferior facet. Fractures of either of the two are common. However, facet dislocation without fracture is also possible since their orientation in the cervical spine is nearly horizontal [3]. This situation has been described with the term 'jumped facets' [4].

* Corresponding author Jiang Hongzhen: Minimally Invasive Spinal Surgery, Beijing Yuhe Integrated Traditional Chinese and Western Medicine Rehabilitation Hospital, Beijing 100853, China; Tel: 086-010-5325 9627; E-mail: XifengZhangChina@hotmail.com

If the facets are locked, the injury may be relatively stable. An unstable injury is often associated with spinal cord injury and neurological deficit. Facet dislocation may be unilateral or bilateral. Anterior displacement may be complete or incomplete. Reduction under cervical traction may be employed to reduce the facet dislocation [5]. However, the risk of neurological deficit following closed reduction exists [6], for which reason, surgical reduction is often considered mainly if the initial attempts at closed reduction are unsuccessful [7, 8]. Unstable fracture-dislocations require surgical decompression and stabilization of the cervical spine [3, 5, 7, 9 - 16].

Optimal initial treatment for these injuries is frequently debated in the neurologically intact patient with, particularly when it comes to surgically treatment of less common unilateral facet injuries or facet injuries without overt instability [6, 17]. Decisions for non-operative or surgical treatment are often based on the consulting surgeon's experience and training [7, 18 - 25]. If surgical treatment is contemplated, a shared decision with the injured patient on how to best return to preinjury functioning may improve satisfaction with the clinical outcome [15]. Delayed surgical treatment of facet dislocations presents their own set of challenges [26 - 31], and spontaneous fusion of the facet joint complex may occur in the long-run [32]. Several studies have been published advocating for anterior only [33 - 35], or a posterior only approach [15]. Most authors recommend combined anterior and posterior reduction and fixation techniques with some precise guidelines when to favor one over the other [14, 22, 29, 34, 36, 37].

To date, the literature suggests that there is not a lot of minimally invasive technology application in the surgical treatment of cervical facet injuries. Typically, these injuries are present as a result of high-energy injuries, often from motor vehicular accidents (MVA) through the emergency room in level I trauma centers. Hence, the emergent nature of the patient presentation is not conducive to minimally invasive spinal surgery techniques. However, its application deserves some thought in terms of simplifying surgical spine care in these often multiply injured patients. Stabilization and clearance of the cervical spine are often the number one question to the spine surgeon involved in level I trauma care as other concomitant extremity-, and pelvis fracture, as well as organ injuries, may require open reduction and internal fixation and other surgical care. In this chapter, the authors describe how they employed the spinal endoscope to assist in the posterior reduction of the jumped facet using a case example. Based on their experience with the technique, they will recommend considering this endoscopic facet joint reduction to simplify the surgical treatment of these grave cervical spine injuries.

AN EXEMPLARY CASE

The authors present their endoscopically assisted cervical facet joint reduction technique using the example of a 50-year-old female. The patient presented to the emergency room with a nine-hour history of severe neck pain and lower extremity paralysis after a high-energy injury to the cervical spine. The patient was accidentally hit into the head by a falling coconut tree while working outdoors. There was a loss of consciousness (LOC) for approximately 10 minutes with a closed head injury resulting in a concussion and cognitive impairment. Upon regaining consciousness, the patient immediately complained of severe neck- and upper extremity pain, and the inability to move her lower extremities.

Moreover, physical examination of the injured revealed neck stiffness, cervical spinous process space, bilateral trapezius muscle tenderness, and no significant sensory loss in both arms. The patient had severely limited cervical spine movement. Motor strength in both arms was limited to 4/5 and 3/5 in the lower extremities, respectively. Both patella tendon reflexes were hyperactive. There was a positive Hoffman's sign bilaterally. The patient had an incomplete spinal cord injury consistent with ASIA Grade D. Advanced imaging examination showed that the C6-7 bilateral cervical facet joints were locked with anterolisthesis of C6 on C7, causing compression of the spinal cord (Fig. 1). Fracture of the right-sided articular process was best visualized with 3D-rendering of the patient's CT-scan (Fig. 2).

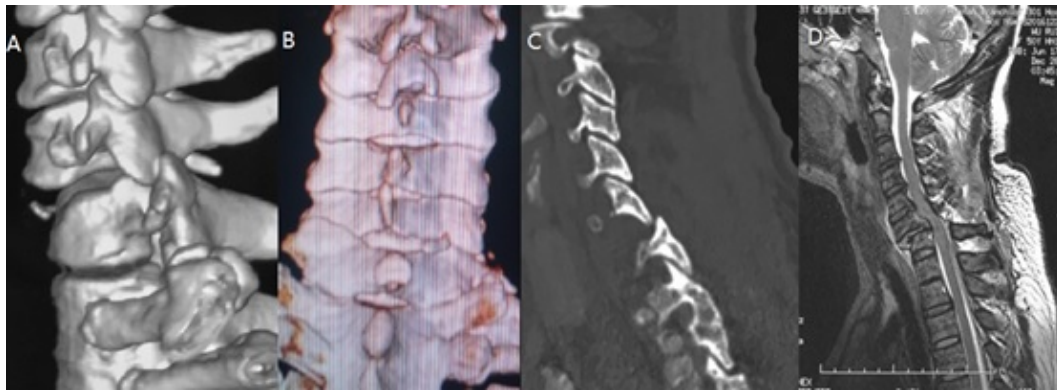


Fig. (1). Preoperative three-dimensional computed tomography (CT) scan (**A**, **B**), and sagittal CT scan showing the locking of the C6-7 facet joint (**C**) with associated spinal cord compression confirmed on the sagittal T2-weighted magnetic resonance image (MRI) (**D**).

CHAPTER 14

Endoscopically Assisted Minimally Invasive Laminoplasty in The Treatment of Cervical Spondylotic Myelopathy

Xifeng Zhang^{1,*}, Li Dongzhe¹ and Jiang Hongzhen¹

¹ Department of Orthopedics, First Medical Center, PLA General Hospital, Beijing 100853, China

Abstract: The authors present a case of cervical myelopathy due to degenerative stenosis of the spinal canal. They employed an endoscope to aid in the improved visualization during the release of ligamentous attachments between the cervical dural sac and the ventral aspect of the cervical lamina during laminoplasty. The patient had two paraspinal 2 cm incisions through which a MED tubular retractor was placed, and most of the bony decompression was done using an operating microscope. The lamina was detached from the lateral masses with a high-speed drill. The bony cuts in this lateral groove were completed with Kerrison rongeurs. Silk stitches were passed through the spinous processes to elevate the cervical laminae from the dural sac and create the posterior expansion of the cord's space. This bilateral laminoplasty was then secured with mini-titanium plates. The authors present their utilization of the spinal endoscope in improved visualization of the surgical dissection, which can be problematic even with an operating microscope through the small exposure afforded by the MED tubular retractor system. The illumination and magnification helped safely execute this hybrid operation that employed two different minimally invasive spinal surgery technologies, including the operating microscope and a spinal endoscope. In the authors' opinion, such hybridizations may be the stepping stone towards next-generation advances in the cervical spine's minimally invasive surgery.

Keywords: Cervical spondylotic myelopathy, Endoscopy, Laminoplasty.

INTRODUCTION

Cervical spondylotic myelopathy (CSM) is a common condition affecting patients with advanced degeneration of the cervical spine leading to a significant reduction of the space available for the spinal cord, which results in decreased neurological function [1 - 9]. Common symptoms include tingling or numbness in the arms,

* Corresponding author Zhang Xifeng: Department of Orthopedics, First Medical Center, PLA General Hospital, Beijing 100853, China; Tel: 086-010-5325 9627; E-mails: XifengZhangChina@hotmail.com and 656780949@qq.com

fingers, or hands, weakness in the arms, shoulders, or hands. Some patients also report trouble grasping and holding on to items. Others describe impairment of their walking ability with the imbalance and other coordination problems, loss of fine motor skills, and pain or stiffness in the neck [10 - 13]. Spinal cord decompression is at the center of surgical treatment. Laminoplasty has been associated with improved clinical outcomes in CSM patients [10, 14 - 19]. Its reported advantages include lower incidence postlaminectomy kyphosis, adjacent segment disease following decompression fusion procedures with lower blood loss, and diminished surgical trauma [12, 18, 20, 21]. The reported disadvantages include axial neck pain and closure of the laminoplasty site with recurrent cervical canal stenosis [8, 22 - 24]. In this chapter, the authors report on their spinal endoscope application during minimally invasive access to the posterior cervical spine during laminoplasty using a MED tubular retractor system. Their hybridized version of the MIS laminoplasty procedure highlights an imminent technology transition in spinal endoscopy from simple uniportal decompression procedures to more complex applications such as reconstructive surgeries of the cervical spine.

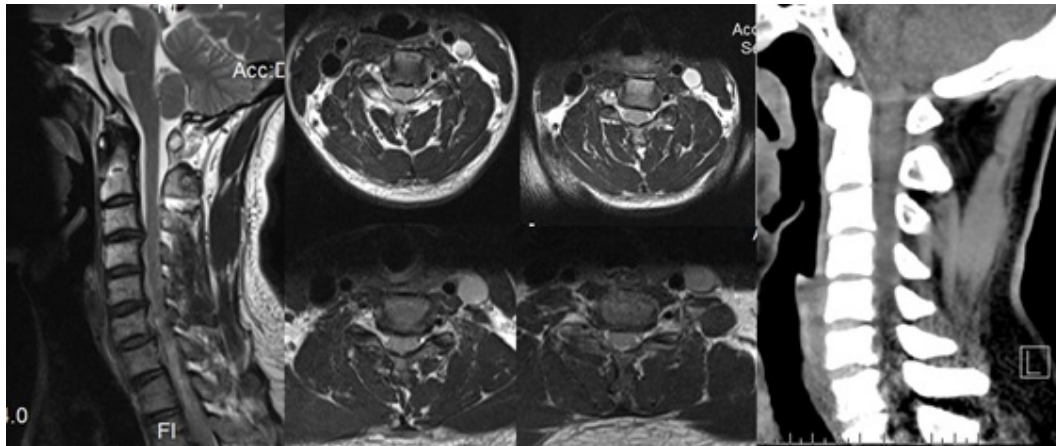


Fig. (1). MRI and CT showed multi-segment cervical disc herniation, cervical spinal stenosis, and no obvious posterior longitudinal ligament calcification.

CASE INTRODUCTION

The patient in a 52-year-old female with a chief complaining of repetitive episodes of the neck- and shoulder pain for more than ten years, which worsened with weakness in the upper- and lower extremities for the last four months before presenting for consultation in our facility. Moreover, the patient reported difficulty holding objects, complained of unstable gait, and limited walking endurance. Physical examination revealed stiffness of the neck muscles and decreased sensation on the radial side of the left forearm and thumb. There was decreased motor strength in the bilateral elbow extensors and flexors 4/5.

Moreover, the grip strength was reduced to 3/5 in both hands. The patient also had a positive Hoffman's sign bilaterally and hyperreflexia in both biceps, triceps, and patella tendon reflexes. The advanced imaging studies showed multi-segment cervical disc herniation and cervical spinal stenosis. Preoperative CT showed a loss of the cervical spine's physiological curvature with straightening without apparent cervical spine instability and calcification of the posterior longitudinal ligament (Fig. 1).

INDICATION FOR SURGERY & TECHNIQUE

The patient had apparent cervical spinal cord compression symptoms, and imaging confirmed cervical spinal canal stenosis and compression of the dural sac. Plain film radiographs showed no evident cervical spine instability. The decision was made to offer the patient a cervical laminoplasty under the MED microscope to expand the cervical spinal canal, thereby improving the cervical spinal cord's compression. The adjunctive use of a spinal endoscope was anticipated for the lysis of adhesions and to aid in the dissection of the dural sac's soft tissue just before lifting the posterior lamina to accomplish the posterior spinal canal expansion.

After induction of general anesthesia and intraoperative administration of perioperative antibiotic coverage for 24 hours, the patient is placed in a prone position, a 20mm long and straight incision is made in the posterior median skin positioned at the C3/4 level. Drill holes are drilled on both sides of each spinous process to pass a silk suture thread through the drill hole intended to aid in lifting the lamina upon completion of the bony cuts. After minimal muscle dissection, a MED tubular retractor was inserted just next to the spinous process until it touches the lamina. After exposing the bone surface, the surgeons' preference was to use a curette to determine the transition from the spinous process to the lateral lower edge of the lamina to the facet joint's medial border.

Before the bony cuts, drill holes were placed at the spinous process base, pointing to the opposite side of the lamina to prepare for micro titanium plate fixation. A high-speed drill to score the bone at the lateral lamina's junction with the medial aspect of the lateral mass. The bone cuts are then completed with the use of the cervical Kerrison rongeur. The bone troughs cut are typically 2-3 mm in width. At this junction, the endoscopic hook is used deployed through a spinal endoscope through the MED tube (> 20 mm) to improve visualization of the soft tissue dissection required to free up the posterior lamina to complete the laminoplasty. The authors found this technique very useful in dissecting and cutting the ligamentum flavum and fiber bundles that are typically attached to the dural sac through the grooved window provided by the bone cuts. Once the dura mater is

CHAPTER 15

A Case Series Report of Endoscopic Debridement and Placement of an Intralesional Catheter for Chemotherapy of Cervical Tuberculosis

Xifeng Zhang^{1,*}, Bu Rongqiang¹, Yuan Heng¹ and Jiang Hongzhen¹

¹ Department of Orthopedics, First Medical Center, PLA General Hospital, Beijing 100853, China

Abstract: The authors present a small case series to demonstrate the feasibility of employing the percutaneous approach to treating cervical spine tuberculosis. They placed a puncture needle under CT-guidance into the abscess to drain and debride pre- and paravertebral and retropharyngeal abscesses with endoscopically assisted technique. A pigtail catheter was placed into the abscess cavity for continuous intralesional delivery of antituberculous chemotherapy. Clinical outcomes were favorable. None of the three patients in this case series report experienced neurological function deterioration or needed more aggressive follow-up surgery. In this chapter, the authors set out to demonstrate the utility of the spinal endoscope in other areas of application distinct from decompression commonly required in degenerative spine disease.

Keywords: Cervical tuberculosis, Endoscopic debridement, Intralesional chemotherapy.

INTRODUCTION

Tuberculosis of the cervical spine can be of devastating consequence to the patient if left untreated. Patients frequently complain of neck pain and stiffness. The fifth vertebral body has been reported as the most commonly involved segment [1]. Multi-drug chemotherapy is still the mainstay of treatment, especially for treating the lower subaxial cervical spine [2]. However, surgical debridement contributions to the overall cure of the disease are still debated [2]. Nevertheless, surgical debridement seems preferred by most spine surgeons. A recent review of the literature, including 456 patients, showed that most of them

* Corresponding author Zhang Xifeng: Department of Orthopedics, First Medical Center, PLA General Hospital, Beijing 100853, China; Tel: 086-010-5325 9627; E-mails: XifengZhangChina@hotmail.com and 656780949@qq.com

(329; 72.1%) underwent surgical debridement. However, the indication for surgery – particularly aggressive debridement – remains controversial. At the same time, surgery has been linked with better recovery of neurologic function.

The additional use of instrumentation maintained better correction of cervical alignment. This chapter's authors stipulated that the high morbidity [3] associated with aggressive surgical debridement of the anterior cervical spine for retropharyngeal abscess and bony destruction could be decreased by minimally invasive endoscopic debridement and decompression of neural elements.

CASE 1

The patient is a 19-year-old male with a chief complaint of pain in the neck, both arms and dysphagia and bilateral arm pain for the last two months. He was transferred to our hospital from a local healthcare facility where physicians considered an infection of the cervical spine in the differential diagnosis after review of the initial spinal imaging studies and a failed one-month trial of anti-inflammatory and other supportive care measures. The patient was placed in a rigid halo orthosis while undergoing workup. Advanced imaging studies including computed tomography (CT) and magnetic resonance imaging (MRI) showed abnormal signals and destruction of the cervical three to six vertebral bodies and a paravertebral phlegmon (Figs. 1 and 2). In conjunction with additional laboratory studies the patient was diagnosed tuberculosis of the cervical spine with a paravertebral abscess. The cervical four and five vertebral bodies were severely damaged resulting in progressive focal kyphosis in spite of the external halo fixation.

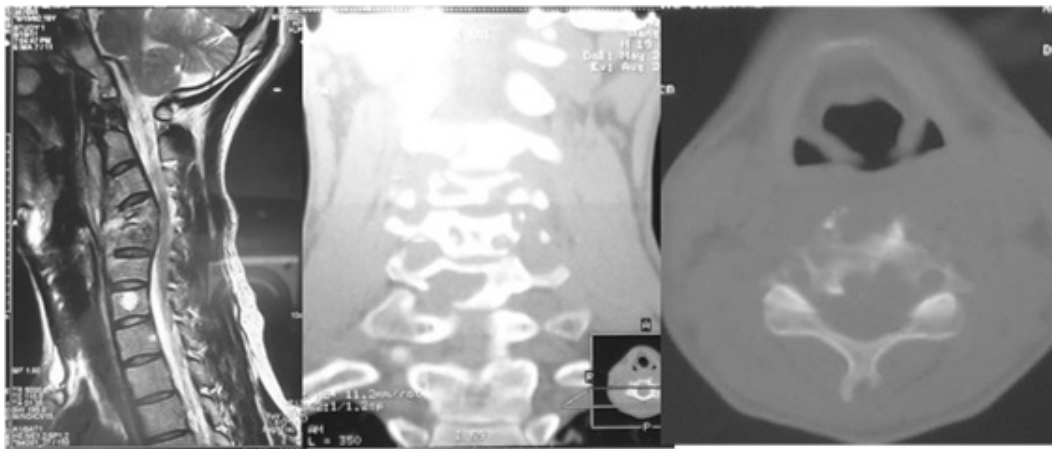


Fig. (1). MRI and CT show abnormal signals of C3-6 vertebral body and paravertebral body, and some bone destruction.

The patient underwent anterior minimally invasive endoscopic approach to the infected area in a supine position under general anesthesia. The access was not tricky after initial dissection *via* serial dilation through the tracheoesophageal groove. The abscessed area was lavaged and carefully debrided under direct endoscopic visualization. At the end of the case, a pigtail catheter was placed into the lesion for local intralesional application of antituberculosis chemotherapy. The regional chemotherapy was continued after the operation for three months under the direction of the infectious disease service, who also confirmed the diagnosis. The postoperative MRI scan showed that the retropharyngeal abscess had disappeared after three months of intralesional treatment. Plain films of the cervical spine showed fusion as well. The patient responded favorably to the endoscopic debridement, followed by three-months of intralesional chemotherapy and continued halo immobilization. Postoperative surveillance studies some three-and-a-half years later showed spontaneous fusion of the disease spinal motion segments (Fig. 3).

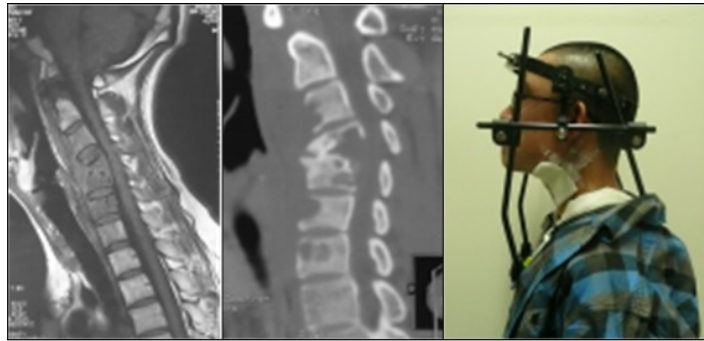


Fig. (2). Three months after the operation, MRI showed that the posterior pharynx's abscess disappeared, CT showed that the C4-5 was fused.

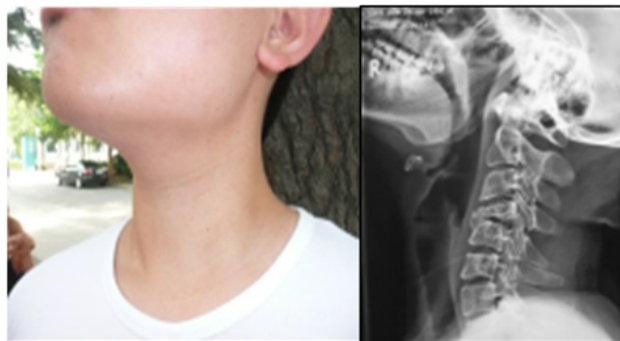

Fig. (3). Follow-up examination 31/2 years after intervention showed spontaneous fusion with minimal focal kyphosis about the cervical four vertebral body.

CHAPTER 16

Cervical Endoscopic Spinal Surgery: Sequela, Failure to Cure, Complications and Their Management

Kai-Uwe Lewandrowski^{1,2,3,*}, Xi Jiancheng, Zheng Zeze⁴, Wang Yipeng⁴, Li Jinlong⁴, Jiang Hongzhen⁴, Stefan Hellinger⁵ and Hyeun Sung Kim^{6,7,8,9,10}

¹ Center for Advanced Spine Care of Southern Arizona and Surgical Institute of Tucson, Tucson, AZ, USA

² Department of Orthopaedic Surgery, UNIRIO, Rio de Janeiro, Brazil

³ Department of Orthopaedic Surgery, Fundación Universitaria Sanitas, Bogotá, D.C., Colombia, USA

⁴ Department of Orthopedics, The Eighth Medical Center, PLA General Hospital, 100091 Beijing, China;

⁵ Department of Orthopedic and Spine Surgery, Arabellaklinik, Munich, Germany

⁶ Department of Neurosurgery, Nanoori Gangnam Hospital, Seoul, Republic of Korea

⁷ A President of the Korean Research Society of the Endoscopic Spine Surgery (KOSESS), South Korea

⁸ A Faculty of the Korean Minimally Invasive Spine Surgery Society (KOMISS), South Korea

⁹ A Chairman of the Nanoori Hospital Group Scientific Team, South Korea

¹⁰ An Adjunct Professor of the Medical College of the Chosun University, Gwangju, South Korea

Abstract: Sequelae and complications following endoscopic surgery of the cervical spine are rare. They may range from neuropraxia, temporary and self-limiting loss of sensation, motor strength, loss of the voice due to recurrent laryngeal nerve injury, vascular and dural leaks to full-blown spinal cord injury with tetraplegia in the worst cases. In this chapter, the authors systematically review the most concerning problems the endoscopic spine surgeon may run into and discuss their management in the context of the most up-to-date peer-reviewed literature. Surgeon training and high skill level are of the utmost importance in minimizing potentially grave outcomes from the cervical spine's endoscopic spine surgery.

* **Corresponding author Kai-Uwe Lewandrowski:** Center for Advanced Spine Care of Southern Arizona and Surgical Institute of Tucson, Tucson, AZ, USA, Department of Orthopaedic Surgery, UNIRIO, Rio de Janeiro, Brazil and Department of Orthopaedic Surgery, Fundación Universitaria Sanitas, Bogotá, D.C., Colombia, USA; Tel: +1 520 204-1495; Fax: +1 623 218-1215; E-mail: business@tucsonspine.com

Kai-Uwe Lewandrowski, Jorge Felipe Ramírez León, Anthony Yeung, Hyeun-Sung Kim, Xifeng Zhang, Gun Choi, Stefan Hellinger and Álvaro Dowling (Eds.)
All rights reserved-© 2021 Bentham Science Publishers

Keywords: Cervical endoscopy, Complications, Failure to cure, Sequela.

INTRODUCTION

The authors trust that the readers of *Contemporary Spinal Endoscopy: Cervical Spine Vol. 1* would not consider their text complete unless there was some discussion of sequela, failure-to-cure scenarios, and complications that could occur during anterior and posterior cervical endoscopy. The endoscopic spine surgeon could encounter any of those in routine clinical practice. Therefore, the authors deem it necessary to discuss some of the pitfalls one should understand and be prepared to manage. They range from incomplete decompression with failure to cure, sequelae defined as unavoidable side effects from an expertly executed surgery, such as neuropraxia or dysesthesia, to outright complications including vascular injury to the carotid sheath or its tributaries, vagal nerve damage, loss of voice, cervical dural tears, and nerve root injuries, and last but not least damage to injury of the cervical spinal cord with grave neurological deficit. While arterial injury can quickly deteriorate into a life-threatening situation that calls for rapid and prompt exploration and intervention with surgical repair, spinal cord injury is undoubtedly the most devastating complication one could encounter as a result of an elective palliative procedure intended to diminish pain. These most severe complications are uncommon to the point where not every one of this chapter's authors has had a case. Therefore, they will present problematic cases that they did have and discuss other problems at least from a theoretical point of view by reviewing the published peer-reviewed literature. Therefore, this chapter is intended to discuss the anatomical basis for peri- and postoperative problems and suggest management protocols the endoscopic spine surgeon should have implemented before embarking on a routine cervical spine endoscopic surgery program.

THE REFERENCES STANDARDS

Using anterior cervical discectomy and fusion as a standard for comparison with anterior cervical endoscopy, the overall morbidity rates for ACDF have been published to be in the range from 13.2% to 19.3% [1]. In descending order, common problems with the ACDF surgery are dysphagia (1.7%-9.5%), postoperative hematoma requiring additional surgery (2.4% of 5.6%), epidural hematoma (0.9%), exacerbation of myelopathy (0.2%-3.3%), symptomatic recurrent laryngeal nerve palsy (0.9%-3.1%), cerebrospinal fluid (CSF) leak (0.5%-1.7%), wound infection (0.1-0.9%-1.6%), increased radiculopathy (1.3%), Horner's syndrome (0.06%-1.1%), respiratory insufficiency (1.1%), esophageal perforation (0.3%-0.9%, with a mortality rate of 0.1%), and instrument failure (0.1%-0.9%) [1]. Internal jugular vein occlusion and a phrenic nerve injury were

only reported in case reports. Pseudarthrosis with ACDF reportedly is dependent on the number of levels fused and may range between 0 to 4.3% (1-level), 24% (2-level), 42% (3 levels) to 56% (4 levels). The reported reoperation rate for symptomatic pseudarthrosis is 11.1%. Readmission rates for ACDF may range from 5.1% (30 days) to 7.7% (90 days postoperatively).

The comparison numbers for posterior cervical foraminotomy have been studied by Skovrij *et al.* who reported the overall complication rates with the minimally invasive version of the posterior foraminotomy as 4.3% [2]. Their study of 70 patients reported 3 patients with complications – 1 patient with a cerebrospinal fluid leak, 1 patient with a postoperative wound hematoma, and another patient with radiculitis. The reoperation rate with ACDF for failure to cure was 7.14% (5/70 patients). Platt *et al.* performed a comparison of outcomes following minimally invasive and open posterior cervical foraminotomy in a systematic review of the literature describing minimally invasive techniques [3]. Employing the Preferred Reporting Items for Systematic Reviews and Meta-Analysis (PRISMA) guidelines the authors searched the PubMed, Cochrane Library, and Scopus libraries for clinical studies comparing minimally invasive posterior cervical foraminotomy (MIS-PCF) to open posterior cervical foraminotomy or percutaneous endoscopic (full-endoscopic) posterior cervical foraminotomy (FE-PCF). A total of 178 abstracts were identified of which 79 full text articles were evaluated. Articles describing laser decompressions or anterior endoscopic techniques were excluded. Platt *et al.* were able to identify 6 eligible studies comparing open to MIS-PCF, including one randomized controlled trial [4 - 9]. Two studies were included in their analysis that compared minimally invasive tubular retractor based posterior cervical foraminotomy to full endoscopic cervical foraminotomy and discectomy [5, 7]. Fessler *et al.* reported no reoperations and three cerebrospinal fluid (CSF) leaks as the only complication in the minimally invasive group including two CSF leaks and one partial thickness dural violation *versus* no complications in the open group [5]. Kim *et al.* (in 2009) had no complications in either group [7]. The complication rates were not statistically different between MIS and open in Winder's *et al.* study [9]. However, reoperations were not specified in three of five studies did not include reoperations [7 - 9]. Another meta-analysis by Fang *et al.* employing the same PRISMA criteria [10, 11] and the Newcastle-Ottawa Scale (NOS) criteria [12] of quality assessment of non-randomized comparative studies [13]. Fang *et al.* found 506 relevant studies, excluded 320 duplicate and 277 irrelevant studies were excluded arriving at 15 studies including 54107 cases which met the the authors predefined inclusion criteria. Three of them were randomized controlled trials [14 - 16], and the other 12 studies were non-randomized comparative studies [17 - 28]. The portion of Fang's meta-analysis relevant for this review of complications with anterior and posterior cervical approaches for cervical radiculopathy revealed

SUBJECT INDEX

A

Ablated intradiscal tissue 7
 Ablation 82 85
 radiofrequency facet 82
 process 85
 Abscess, posterior pharynx's 221
 Access 204, 243
 puncture needle 243
 trauma 204
 Adjacent segment disease (ASD) 8, 12, 109,
 117, 118, 127, 149, 157, 173, 187, 210
 Aggressive postoperative rehabilitation
 programs 246
 Ahn's study 238
 Airway obstruction problems 38
 Ambulatory surgeries 33
 American spinal injury association scoring
 system 115
 Analysis, retrospective 53
 Anesthesia 31, 32, 33, 34, 35, 38, 50, 98, 103,
 110, 142, 143, 144, 145
 ambulatory 35
 balanced 32, 38
 deep 31, 32
 Anesthesia 32, 37, 189
 care 189
 protocols 32, 37
 strategies 32
 Anesthesiologists 31, 32, 33, 34, 35, 38, 85,
 144
 Anterior cervical 1, 11, 45, 66, 76, 103, 110,
 135, 140, 157, 187, 194, 195, 237, 242,
 244
 decompression and fusion 157, 195
 discectomy 1, 11, 66, 103, 110, 135, 187,
 194
 full-endoscopic 11
 endoscopic discectomy (ACED) 45, 237,
 242, 244
 full-endoscopic surgery 140

 procedures 76
 Anterior 12, 64, 128, 130, 135, 192
 endoscopic cervical foraminotomy (AECF)
 64, 128, 130, 135
 intervertebral height (AIH) 12
 ring apophysis 192
 Anterolisthesis 202
 Antituberculosis chemotherapy 221
 Artificial disc replacement (ADR) 149, 187
 Ascher technique 8
 Athetoid movements 83
 Athetosis infantile 83
 Autograft 185, 194
 bone dowel 185
 fusion surgery 194

B

Biomechanical studies allude 69
 Bladder dysfunction 53
 Bone 76, 116, 117, 186, 191, 193, 194, 225,
 227, 228
 graft 76, 117, 186, 191, 193, 194, 228
 grafting 227
 healing 116
 loss 225
 Bony 64, 142, 209
 decompression 64, 209
 foraminal stenosis 142
 Bradycardia 36, 38

C

Cadaver-based study 236
 Cardiac arrest 242
 Cardiopulmonary arrest 246
 Carotid artery injury 14
 CCD video camera 145
 Cerebral palsy (CP) 83
 Cerebrospinal fluid leak 232

- Cervical 7, 8, 12, 13, 14, 45, 48, 53, 54, 62, 63, 65, 68, 71, 72, 73, 83, 84, 89, 90, 115, 116, 127, 131, 134, 139, 140, 141, 148, 149, 172, 173, 166, 174, 176, 178, 185, 186, 187, 209, 211, 215, 222, 240
canal stenosis 71, 72
chemonucleolysis 187
chordotomy 84
disc arthroplasty 8
hematoma 116
interbody fusion 187
laminoplasty 211, 215
MRI 222
myelopathy 12, 53, 65, 71, 73, 115, 116, 127, 176, 209
nerve roots 45, 48, 54, 62, 68, 83, 89, 90, 166, 174, 178
pain syndromes 185, 186
radiculopathy (CR) 7, 12, 13, 14, 127, 134, 139, 140, 141, 148, 149, 172, 173
RF rhizotomies 84
rhizotomy procedure 83
spondylopathy 240
stenosis 63, 65, 127
thermodiscolasty 131, 134
Cervical decompression 32, 36, 38, 7, 39, 46, 128, 237, 246
surgery 32, 36, 38
Cervical disectomy 6, 148
procedure 6
technique 148
Cervical disc 10, 11, 12, 13, 14, 15, 53, 73, 74, 75, 109, 115, 116, 185, 186, 210, 211
herniation (CDH) 10, 11, 12, 13, 14, 15, 53, 73, 74, 75, 109, 115, 116, 210, 211
surgery, traditional 186
syndromes, symptomatic 185
Cervical spinal 13, 31, 44, 129, 231
surgeries 13, 31, 44
endoscopic surgery 129
endoscopic surgery program 231
procedures 76
Chi-Square test 163
Chronic 5, 38, 141
obstructive pulmonary disease (COPD) 38
pain syndromes 5
radiculopathy pain 141
Comparison of open cervical spine surgery 64
Compressive 44, 49, 52, 54, 157, 158, 159, 161, 165, 237, 238
lesions 158, 237
pathology 44, 49, 52, 54, 157, 158, 159, 161, 165, 237, 238
Computed tomography (CT) 43, 48, 115, 116, 141, 158, 161, 162, 175, 202, 204, 220, 221, 224, 243
angiogram (CTA) 243
coronal reconstruction 116
Computer tomography 175
Contemporary 2, 231
endoscopic spinal surgery 2
spinal endoscopy 2, 231
Cord 72, 179, 201, 230, 231, 244, 245, 247
deformity, spinal 72
injury, spinal 179, 201, 230, 231, 244, 245, 247
Corpectomy 14, 108, 165
C-reactive protein (CRP) 227
Cricothyroid 235
CTA, cervical vascular 243
CT 117, 127, 140, 149, 150, 175, 203, 214
data 140
scans 117, 127, 149, 150, 175, 203, 214
- D**
- Decompression sites 111, 159
Deformity, spinal 227
Degeneration, advanced 95, 109, 139, 150, 209
Degenerative 127, 172
processes 127
spinal disease 172
Demyelination 66
Disc 115, 116, 117
herniation, calcified 115
space narrowing 116, 117

Disease 3, 8, 38, 45, 48, 65, 87, 129, 157, 158, 173, 185, 186, 219, 221, 227
 cardiopulmonary 38
 cervical degenerative 158
 cervical discogenic 185
 cervical spine neurodegenerative 173
 chronic obstructive pulmonary 38
 degenerative 48
 degenerative spine 219
 hematological 87
 symptomatic degenerative cervical disc 8
 Dorsal root ganglion (DRG) 10, 11, 83
 Durotomy 151, 152
 Dysesthesias 141, 179, 231, 233, 240
 Dysfunction syndromes 237
 Dyskinetic syndromes 83
 Dysphagia 12, 44, 108, 115, 117, 119, 157, 220, 228, 231, 235

E

Edema 66, 245
 Electrophysiological tests 65
 Endoscopic 31, 43, 45, 49, 51, 54, 63, 85, 103, 105, 120, 128, 129, 132, 134, 186, 187, 188, 215, 219, 221, 222, 227, 238, 247
 abrasion tools 85
 debridement 219, 221, 222, 227
 decompression surgery 31, 247
 differentiation 132
 discectomy surgery 45
 index surgery 238
 laminectomy 159
 rongeurs 104, 166
 surgery techniques 43, 52, 75, 141
 systems 238
 techniques 49, 51, 54, 103, 105, 118, 120, 128, 129, 134, 186, 187, 188
 technology 63
 treatment 43
 visualization 215
 Equipment, modern cervical endoscopy 244
 Erythrocyte sedimentation rate (ESR) 227

F

Facet 173, 201
 arthropathy 173
 hypertrophy 173
 injuries 201
 Fang's meta-analysis 232
 Feasibility, technique's 228
 Fenestrotomy 186
 Fingers, surgeon's 131
 Fluoroscopic 99, 119, 131, 143, 144, 146, 242
 anterior-posterior 242
 images 119
 lateral intraoperative 112
 Fluoroscopy 100, 111, 145, 146, 177
 images 145
 Focal kyphosis 54
 Foraminal stenosis 46, 47, 48, 49, 53, 71, 74, 75, 76, 142, 146, 179, 181
 bilateral symptomatic 76
 cervical neural 48
 symptomatic cervical 49
 Foraminoplasty 133
 Foraminotomy 7, 37, 44, 63, 75, 135, 140, 144, 145, 146, 147, 152, 181
 technique 135, 146
 Full-endoscopic cervical discectomy (FECD) 11, 46
 Function 34, 36, 38, 115, 187, 220, 235, 242, 246
 biomechanical 187
 cardiopulmonary 242
 cardiovascular 34
 neurologic 115, 220
 respiratory 36, 38

G

General anesthesia (GA) 33, 38, 39, 100, 103, 110, 140, 142, 143, 144, 200, 204, 211

H

Hallmark symptom 140

Halo orthosis 220
 Hattori's theory 73
 Headaches 8, 188
 Hematoma 233, 246
 Hemilaminectomy 186
 Hemiparesis 246
 Hemodynamics 34
 Hernias 46, 100, 128
 Horner's syndrome 108, 119, 231
 Hydraulic pressures 118, 177
 Hypertrophic tissue 128
 Hypertrophy 160
 Hypophonation 235
 Hypotension 35, 36, 38, 246
 Hypoventilation 35

I

Iatrogenic injury 45, 108, 119, 120
 Imaging 43, 65, 66, 111, 115, 141, 175, 211, 220
 biplanar fluoroscopic 111
 magnetic resonance 43, 65, 66, 115, 141, 175, 220
 Implant-related problems 157
 Infections, degrease 234
 Inflammatory cytokines 149
 Innovative technology and techniques 44
 Instability, post-laminectomy 5
 Intensive care unit (ICU) 246
 Internal jugular vein occlusion 231
 Interventional pain management 1
 Intralesional chemotherapy 219, 221
 Intraoperative 109, 118, 139, 143, 161, 162
 endoscopic images 139
 fluoroscopic images 161, 162
 iatrogenic injury 109, 118
 neuromonitoring 143
 Intraoperative fluoroscopy 110, 111, 119, 182, 189, 212
 images 110

J

Japanese orthopaedic association (JOA) 12, 13, 54, 115, 156

K

Key opinion leaders (KOLs) 2, 4
 Kyphosis 46, 47, 49, 50, 74, 94, 172, 176, 225, 228, 240
 lower incidence postlaminectomy 210
 multilevel 74
 post-decompression 172
 pronounced 240
 segmental 94
 significant cervical 176
 Kyphosis rates 151
 Kyphotic deformity 53
 excessive focal 226

L

Laminoplasty 157, 209, 210, 211, 214, 215
 bilateral 209
 segment 215
 technique 157
 Laryngeal mask airway (LMA) 31, 38, 39, 85, 142, 189
 Laser technology 76
 Lateral cervical canal stenosis 44, 126, 134
 Ligamentum flavum hypertrophy 158
 Light inhalation anesthesia 38
 Longus colli muscle (LCM) 99, 119
 Loss 76, 202
 segment motion 76
 significant sensory 202
 Lower cervical spine 227
 Lower limb 158
 dysfunction 158
 motor dysfunction 158

M

MAC anesthesia 54
 Mac Nab's 148, 181
 criteria 148
 score 148, 181
 Magerl technique 212
 Magnetic resonance imaging (MRI) 43, 48,
 65, 66, 115, 141, 173, 175, 220, 221,
 223
 Maneuver 188
 Massage therapy 222
 Microendoscopic Kerrison 63
 Microendoscopy 234
 Microsurgical 54, 109, 117, 212
 dissection 54
 laminoplasty 212
 techniques 109, 117
 Minimally invasive 44, 62, 64, 75, 82, 126,
 127, 129, 135, 139, 140, 152, 172, 181,
 201, 230, 232
 spinal surgery techniques (MISST) 62, 126,
 127, 140, 152, 201
 spine (MIS) 44, 64, 75, 82, 126, 129, 135,
 139, 172, 181, 230, 232
 MIS techniques 44, 118, 135
 Monitored anesthesia care (MAC) 31, 32, 33,
 34, 36, 39, 47, 51, 53, 103, 129, 143,
 144
 Motion 150, 190, 222
 limited neck 222
 preserving neck 150
 rotating 190
 Motion preservation 14, 94, 95, 103, 108, 149,
 157, 181
 procedure 95
 strategies 108
 surgery 94, 149
 Motor vehicular accidents (MVA) 201
 MRI 146, 224
 images 146
 lesions 224
 Myelomalacia 66

N

Narcotic 5, 135
 independence 5
 utilization 135
 Neck disability index (NDI) 10, 13, 14, 63,
 65, 88, 89, 103, 104, 134
 Necrosis 66
 Nerve 141, 235 242
 conduction studies (NCS) 141
 injury 235
 lysis 242
 Nerve root 45, 73, 175, 215
 compression 45, 73
 dysesthesia 175
 palsy 215
 Neural 4, 33, 64, 103, 147, 148, 174, 178, 179,
 180, 181, 183, 220
 elements 4, 64, 103, 148, 174, 178, 179,
 180, 181, 220
 injuries 33, 181
 retraction 147, 178, 179, 183
 Neurectomy procedures 37
 Neuroforamen 101, 127, 152, 239
 surgical 239
 Neurological 2, 45, 174, 180, 200, 201, 204,
 227, 231, 244, 245, 246
 complications 174, 200
 Neurological deficits 2, 45, 127, 129, 180,
 201, 204, 227, 231, 244, 245, 246
 progressive 127
 severe 129, 246
 Neurologic deficit 244
 Non-endoscopic percutaneous procedures 187
 Non-narcotic pain medication 103
 Nuclear decompression procedure 190
 Nucleoplasty 129

O

Operation lasting time 164
 Ossification 129, 165
 Ossified posterior longitudinal ligament
 (OPLL) 49, 54, 128

Osteophytes 127, 128, 132, 135, 165, 175
 Osteophytosis 103
 Oswestry Disability Index (ODI) 148, 181
 Outcomes 173, 210
 excellent clinical 173
 improved clinical 210

P

Pain 9, 11, 33, 34, 35, 84, 88, 89, 141, 185,
 186, 228, 231, 234, 240
 cervical 186
 chronic 88
 management 9
 Palsy 83, 45, 174, 175, 231
 cerebral 83
 postoperative C5 nerve 45
 symptomatic recurrent laryngeal nerve 231
 PECD 50, 150, 151, 152
 decompression 150
 technique 50, 150, 151, 152
 Pediclectomy 234
 Percutaneous endoscopic 8, 13, 14, 54, 75,
 105, 108, 109, 115, 140, 148, 149, 150,
 151, 152, 234, 238
 cervical discectomy (PECD) 13, 54, 75,
 105, 108, 109, 115, 140, 148, 149, 150,
 151, 152, 234, 238
 laser surgery 8
 surgery 14
 Physical therapy (PT) 10, 82, 87, 88, 89, 103,
 141, 157, 186, 215
 Pituitaries 104, 190
 Point PECD technique 139
 Posterior 6, 8, 47, 48, 62, 63, 102, 113, 129,
 132, 140, 144, 149, 150, 151, 165, 172,
 173, 174, 177, 178, 181, 183, 187, 190,
 211, 232, 233, 234
 cervical foraminotomy (PCF) 62, 63, 140,
 144, 149, 150, 151, 173, 181, 187, 232,
 233, 234
 endoscopic cervical foraminotomy (PECF)
 47, 48, 63, 172, 173, 174, 177, 178, 183

 longitudinal ligament (PLL) 6, 8, 102, 113,
 129, 132, 165, 173, 190, 211
 Preoperative and post-operative CT 148
 PRISMA criteria 232
 Procedure 9, 90, 98, 190, 231
 cervical 98
 dental 9
 laminotomy 90
 palliative 231
 transcorporeal 109
 Program directors 2
 Puncture needle, sharp vertebroplasty 111

R

Radiating pain 127
 Radiculitis 84, 232
 cervical 84
 Radiculopathy 9, 12, 43, 48, 76, 83, 84, 86,
 89, 90, 115, 127, 142, 173, 176, 179,
 181, 186
 syndrome 48
 ablation 9, 83, 84, 86, 179
 denervation procedure 89, 90
 Radiographic 64, 238
 changes 238
 evaluation 64
 Radiographs 204
 Radiography 127
 Radiological evaluation 150
 Recurrent laryngeal nerve (RLN) 66, 108,
 115, 117, 119, 187, 230, 231, 234, 235,
 236
 Rhizotomy 83, 84
 bilateral cervical posterior 83
 cervical dorsal 84
 RLN injury 235, 236

S

Sedation, ambulatory surgery 35
 Sensory function 85, 164
 Shoulder arthroscopy 104
 Skin 51, 85, 111, 131, 158, 189, 211

- incision 51, 85, 111, 131, 158, 189
- posterior median 211
- Social reintegration 5
- Soft 103, 177, 180
 - mechanical foods 103
 - tissue dissection & bone drilling 177
 - tissue recovery 180
- Spinal 2, 4, 6, 33, 62, 63, 67, 84, 87, 101, 109, 158, 165, 174, 201, 209, 214, 215, 219, 236, 246
 - endoscopy, laser-assisted 6
 - nerves 33, 84
 - stenosis 3, 158
 - surgeons 2, 4, 62, 63, 67, 109, 201, 219, 236
 - canal 87, 101, 165, 174, 209, 214, 215, 246
- Spinal cord 2, 44, 45, 54, 65, 72, 73, 116, 147, 148, 157, 158, 164, 165, 166, 167, 178, 180, 181, 182, 186, 210, 246
 - compression 44, 45, 73, 118, 157, 158, 165, 200, 237
 - damage 2
 - decompression 158, 164, 165, 166, 167, 210
 - degeneration 157, 158
 - disease 65
 - dysfunction 116, 157, 186
 - function 165
 - reaction 246
- Spinal endoscope 3, 9, 46, 52, 54, 85, 97, 201, 209, 211, 212, 214, 219
 - cervical 46, 52, 97
- Spinal surgery 64, 94, 233, 240
 - practice 240
 - program 233
 - techniques 64, 94
- Steroid therapy 246
- Surgical 4, 14, 43, 44, 52, 54, 73, 85, 94, 105, 110, 128, 130, 134, 144, 145, 157, 186, 188, 194, 200, 233, 234, 236
 - anatomy 54, 134
 - CSM treatment 157
 - procedures 4, 44, 73, 94, 128, 186, 188
 - risks 200

- techniques 14, 43, 85, 105, 110, 130, 144, 145, 233
- trauma 52, 194, 234, 236
- Symptoms 65, 89, 90, 109, 115, 132, 135, 164, 165, 185, 234, 235, 240, 242
 - facetogenic 90
 - neurological 185
 - resolution 135

T

- Target-controlled infusion (TCI) 35
- TB lesions 228
- Techniques 54, 64, 75, 76, 120, 126, 127, 134, 135, 140, 172, 185, 187, 188, 200, 201, 215, 216
 - cervical 75, 134, 135
 - contemporary 140
 - endoscopic interbody fusion 185
 - invasive surgery 54
 - transdiscal discectomy 120
- Tissue(s) 9, 64, 99, 188, 194
 - damage 64
 - dissection 9
 - prevertebral 99, 188
- Tissue trauma 11, 166
 - reduced 166
- Torticollis 83, 224, 240
- Tracheoesophageal injury 108
- Traction, excessive 98, 234
- Traditional 63, 80
 - cervical management 63
 - posterior cervical decompression technique 180
- Trajectory 14, 110, 129, 158
- Transcorporeal PECD 108, 118, 119
- Transition syndrome 63
- Transverse process 109, 119
 - cervical 109
- Treatment 221, 222, 246
 - intralesional 221, 222
 - steroid 246
- Tuberculosis 219, 220, 224, 226, 227, 228
 - diagnosed 220

- lesions 227
- Tubular 49, 52, 97, 102, 179, 181, 209, 211, 212, 213
 - Kerrison 97, 102
 - posterior cervical foraminotomy 181
 - retractor 49, 52, 179, 209, 211, 212, 213
- Tubular retractor 54, 209, 210, 239
 - surgery 54
 - system 209, 210, 239
- Tumors 83, 142, 235
 - cancerous 235
 - malignant 83

V

- Vaporizing tissue 7
- Vascular injury 105, 116, 117, 231, 239, 240, 247
- Vertebral body fracture 179
- Video technology 3
- Vision, surgeon's 181
- Visual analogue scale (VAS) 11, 12, 13, 63, 65, 103, 104, 115, 116, 132, 134, 140

W

- Wound 113, 145, 159, 194, 212, 226, 231, 233, 237
 - hematoma 194, 233
 - infection 231, 233



KAI-UWE LEWANDROWSKI

Dr. Lewandrowski has dedicated his career to developing and implementing formalized endoscopic spinal surgery protocols by applying his NIH- and SBIR-funded academic research background to clinical investigation with sophisticated statistical analysis. His acumen has enabled him to build an entrepreneurial outpatient spinal surgery program that provides quality medical care to many patients.



JORGE FELIPE RAMÍREZ LEÓN

Dr. Ramirez is the number one key opinion leader in the Spanish-speaking world - an entrepreneur innovator spine surgeon who has advanced spinal endoscopy as a physician, business owner, and current or past president of the leading Latinamerican spine societies.



ANTHONY YEUNG

Dr. Yeung is the world's most renowned spinal endoscopist who was there at the beginning when it all started some 35 years ago. He was one of the first in the United States to begin his own vertically integrated ambulatory surgery center focused on endoscopic outpatient spine care.

The cervical spine has long been a controversial and difficult area of endoscopic surgery. Higher surgical risks and skill level requirements have often hampered the enthusiasm of spinal endoscopists to tackle this part of the spine. Recently, cervical spine surgery has gained attention in the medical community, and technology advances with improved miniaturized optical and surgical access systems are showcased by expert spine surgeons in a growing number of publications. In response to the unmet demand for a standard text, the editors have developed a multi-authored and clinically focused medical monograph entitled Contemporary Endoscopic Spine Surgery: Cervical Spine to give the reader an updated snapshot of the current state-of-the-art of cervical spinal endoscopic surgeries.



International Intradiscal Therapy Society



SLAOT